



Variation in Mental Foramen of Mandible among South Indian Population- A Radiographic Analysis

S. P. Ashwin^a and Lavanya Prathap^{b†}

^a *Saveetha Dental College and Hospitals, Saveetha Institute of Medical and Technical Sciences, Saveetha University, Chennai – 600077, India.*

^b *Department of Anatomy, Saveetha Dental College and Hospitals, Saveetha Institute of Medical and Technical Sciences, Saveetha University, Chennai – 600077, India.*

Authors' contributions

This work was carried out in collaboration between both authors. Both authors read and approved the final manuscript.

Article Information

DOI: 10.9734/JPRI/2021/v33i60B35035

Open Peer Review History:

This journal follows the Advanced Open Peer Review policy. Identity of the Reviewers, Editor(s) and additional Reviewers, peer review comments, different versions of the manuscript, comments of the editors, etc are available here: <https://www.sdiarticle5.com/review-history/78958>

Original Research Article

Received 23 October 2021

Accepted 27 December 2021

Published 28 December 2021

ABSTRACT

Background: The mental foramen (MF) is a hole in the body of the mandible that is placed on the antero-lateral side. Between the upper and lower mandibular borders, it can be found. It sends signals to the brain's nerves and blood vessels. Many researches have documented variations in the placement of the MF among different ethnic groups, as well as variations in its forms. It's commonly found beneath the first premolar teeth. The study's goal is to look at where mental foramen are found in the South Indian population.

Materials and Methods: A total of 100 distinct OPGs from the South Indian population were used in the investigation. The position of mental foramen for various mandibles was visually examined using OPGs, and the data was tallied and analyzed using SPSS.

Results: From the results it is suggested that the maximum frequency for the right side is at location 2 which is in the longitudinal axis of 1st premolar. 14.0% at location 1, 31.6% at location 2, 21.1% at location 3. 17.3% at location 4. 10% at location 5, 6% at location 6. The situation of mental foramen at the axis of 1st premolar was observed to have a high frequency of occurrence in the age group of 26-35.

Conclusion: The Mental foramen in study population is mostly found in the longitudinal axis of 1st premolar. The clinical students and surgeons should know the existence of mental foramen at surgical procedures using mandibular premolar and molar regions. Future studies with large sample sizes should be conducted to make the results conclusive.

[†]Associate Professor;

[‡]Senior Lecturer;

*Corresponding author: E-mail: lavanyap.sdc@saveetha.com, lavanya.anatomist@gmail.com;

Keywords: Mental foramen; OPG; mandible; radiography; innovative technique.

1. INTRODUCTION

The Mental Foramen (MF) is placed midway between the top and bottom margins of the mandible's body. It runs parallel to the supraorbital notch between the two premolars. The foramen is the departure point for mental vessels and nerves [1]. An orthopantomogram can be used to determine the position of the mental foramen (OPG). The mental foramina are usually depicted in a postero-superior position. Many studies have shown that the MF is placed differently in different ethnic groups, as well as in distinct shapes. It's usually seen under the first premolar. The branches of the mental nerve and veins may use this mental foramen. Dental surgeons would benefit greatly from fine knowledge of the variations in the different dimensions of the mental foramen, and thus the appearance of the accessory mental foramen, when performing surgical procedures on the mandible, [2] Prior to surgery, it is also critical to have an effective and successful anaesthesia during nerve blocks. Various authors have reported on numerous studies on the South Indian people. As a result, we attempted to discover the most common position and size of the mental foramen in adult South Indians in our current study [3]. The experience from our previous studies [4-13] have led us to focus on the current topic.

MF is usually single in human beings; If Accessory mental foramen is present, MF transmit either the accessory mental nerve, which It itself may be a branch of inferior alveolar nerve, or one among the branches of mental nerve [14]. These auxiliary mental foramen (AMFs) are located on the perimandibular area surrounding the MF and are usually smaller than the MF. Failure to detect and protect MF and the structures that cross it would be the reason for a lack of proper mental nerve anaesthesia. It can cause neurosensory problems or traumatic neuroma if the accessory nerves are accidentally damaged. Our team has a wealth of research and knowledge that has resulted in high-quality publications [15–34]. The study's goal is to look at where mental foramen are found in the South Indian population.

2. MATERIALS AND METHODS

This is a retrospective study conducted in a private dental college and hospital in Chennai

using 100 OPG's. Patients aged 1 year and above and High quality OPG's with respect to coloration and angulation were included. Exclusion criteria-Patients affected with dental and maxillofacial fractures, joint disjunction, traumas, pathological lesions around mental foramen were excluded and Patients undergoing diagnosis surgery or orthodontic purposes were excluded from the study. Data were analyzed statistically by SPSS 2.3. Data was set and analysed by chi square test with bar charts and cross tabs. The study was approved by the institutional review board. The OPG'S of the South Indian population were taken and the location of the mental foramen is located and the data were added in sheets and statistically analysed in SPSS. The locations were classified by 6 different locations (Table 1). The locations were entered and statistically analysed by SPSS.

Table 1. Representing different locations of mental foramen based on It is position

Locations	Positions
1	Between canine and 1st premolar
2	Axis of 1st premolar
3	Between 1st and 2nd premolar
4	Axis of 2nd premolar,
5	Between 2nd premolar and 1st molar
6	Axis of 1st molar.

3. RESULTS

From the results it is suggested that the maximum frequency for the right side is at location 2 which is in the longitudinal axis of 1st premolar. 14.0% at location 1, 31.6% at location 2, 21.1% at location 3. 17.3% at location 4. 10% at location 5, 6% at location 6. The location of mental foramen at the axis of 1st premolar was observed to have a high frequency of occurrence in the age group of 26-35. (Figs. 1,2 represented in different age groups with error bars).

4. DISCUSSION

The location of the vertical axis of the 1st premolar has the maximum frequency among the 100 OPG's in the South Indian population. The Most frequent frequency was 14.0% at location 1, 31.6% at location 2, 21.1% at location 3. This study can have It is own relevance and has forensic importance [35,36]. The MF is typically directed postero-superiorly and is situated on the

anterolateral aspect of the body of the mandible. It is usually located below the interval between the premolars, midpoint between the inferior and the alveolar margins of the mandible, and approximately thirteen to fifteen millimeter

superior to the inferior border of the mandibular body. Variations are observed in its location, which may be more anterior, below the canine or posterior, and close to the second molar [37].

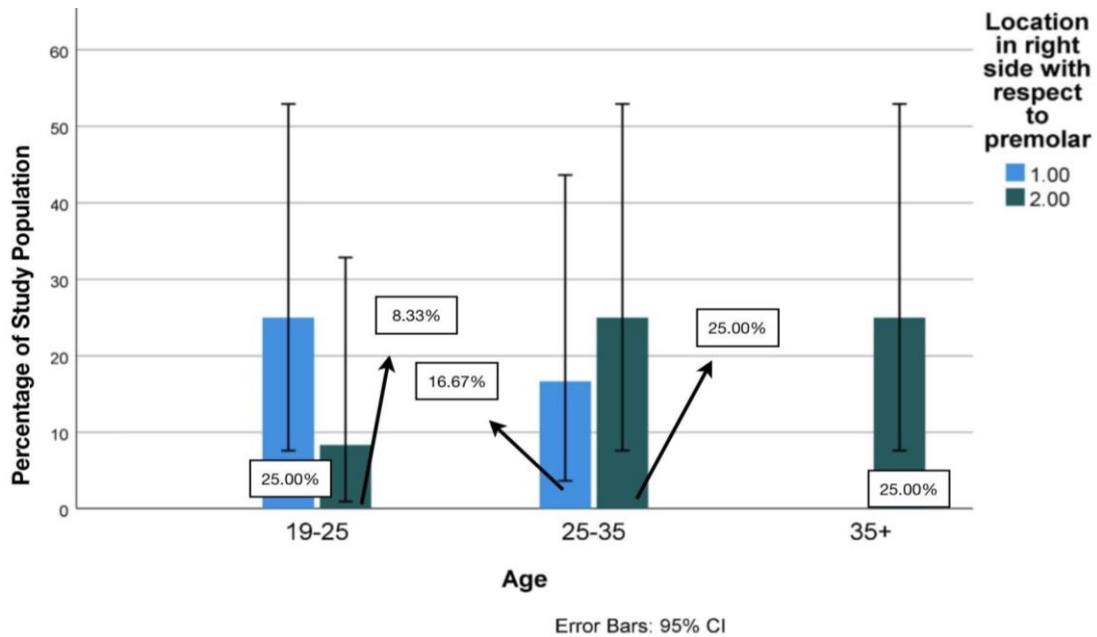


Fig. 1. This graph represents the comparison analysis of the location of mental foramen in the right side with respect to age groups. X-axis presents locations of mental foramen the y axis presents the number of the samples

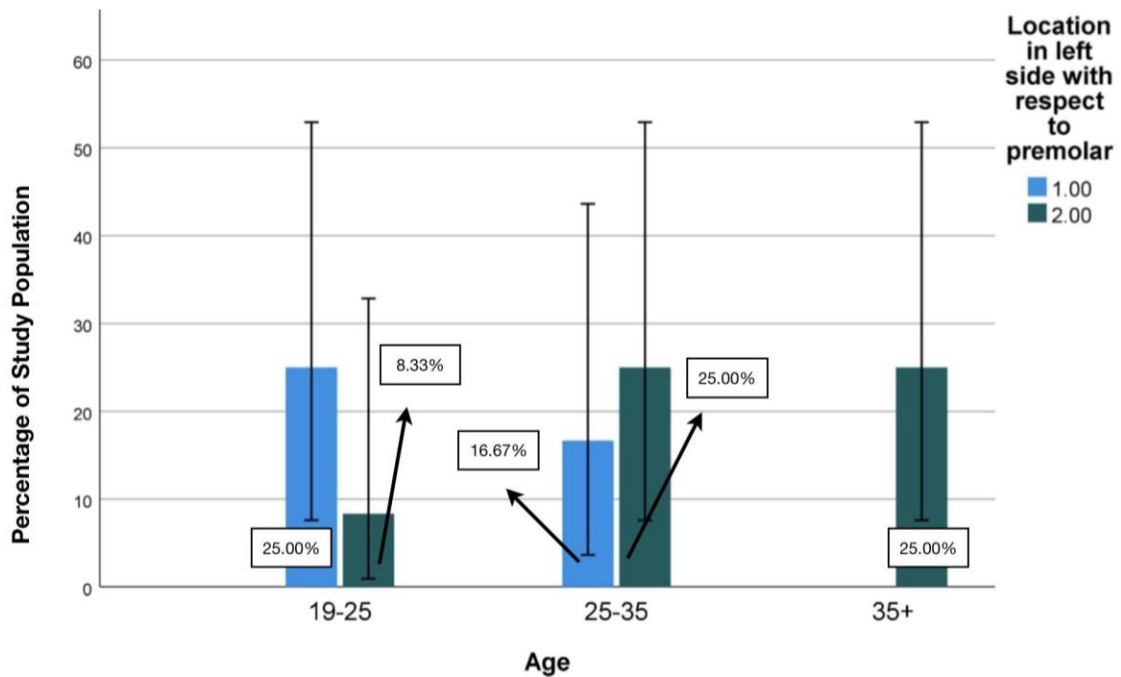


Fig. 2. This graph shows the comparison analysis of the mean situation of mental foramen in the left side between age groups. X axis presents the different locations of mental foramen. Y axis presents the count of population with respect to the location

MFs are typically seen underneath the primary molar and premolar teeth, according to previous research. Though it was found in a variety of places in the current investigation, it was found below the second premolar in 48 percent of the cases [38]. As previously stated, the bulk of the MF were found in the distal part of the MF, with only a few in the mesial region. The majority of the time, MF was discovered to be located inferior to the MF. AMF were found to be behind MF [39]. The presence of AMF in relation to MF could have an impact on the rehabilitation therapy planning since it would interfere with implant processes. The majority of the MF in this study were either inferolateral (25.9%) or superomedial (25.9%) to the MF [40].

The most common MF location in the anterior-posterior position, There was an edge inbetween the primary and 2nd mandibular premolars, which was typical of older patients on the right side, and then a situ within the vertical axis of the 2nd mandibular premolars, which was typical on right side of younger patients, regardless of gender of the themes [41]. In every case when CT technologies were used, the outcomes of our studies matched the findings of the research. There were no changes in the dimensions of MF based on the age of the themes. However, significant differences in the dimension of MF were found in connection to the patients' gender. In comparison to women, men have a larger vertical dimension on two sides of the mandible and a larger horizontal dimension on the correct side of the jaw [42].

Dental implants and other surgery can be easily done by the identification of the mental foramen and it is location, preparation for the surgery can be easily made according to the requirements.

MF are a rare anatomical variation and reported to possess a prevalence starting from 1.4% to 10%. [43]. The presence of MF has been reported by investigations on dry human skulls, cadaveric dissections, and radiological studies. In a previous study, the incidence in the South Indian population was found to be 8.85%. % MF were found on the left side of the brain more than the right side in this study. This is consistent with prior research, which discovered 8% MFs on the left side and 5% on the right; 3.33 percent MFs on the left side and a few.22 percent on the right side. 4 MF were found on the right side of the mandible, according to [44] Bilateral MF has been documented in just 0.53 percent of the population, according to previous investigations [45]. In contrast, 2 percent of the South Indian

population has been observed to have bilateral MF.

A study revealed 1.6% bilateral MF, indicating that bilateral MF occurrence is more in Indian population. The nerve flowing through the MF is hypothesised to influence the location and size of the MF. The mental nerve has four terminal branches: angular, medial inferior labial, lateral inferior labial, and mental branches [46]. The nerve emerging from MF has been described as either being one among the terminal branches of mental nerve given off within the mandibular canal or the presence of a further branch, called accessory mental nerve which is taken into account to be a branch of the inferior alveolar nerve which could have separated earlier than formation of mental foramina. Limitations of this study are limited sample size, random sampling, ethical issues in identifying opg's and names that can't be revealed and the data collected are highly confidential. Future studies should be conducted with a huge sample size to make the context evident and it may have forensic and surgical implications.

5. CONCLUSION

The Mental foramen in South Indian population is mostly found in the longitudinal axis of 1st premolar. The clinical students and surgeons should know the existence of mental foramen at surgical procedures using mandibular premolar and molar regions. To make the findings conclusive, other studies with large sample sizes should be done.

CONSENT

It's not applicable.

ETHICAL APPROVAL

As per international standard or university standard written ethical approval has been collected and preserved by the author(s).

ACKNOWLEDGEMENT

We thank Saveetha Dental College and Hospitals for the successful completion of the study.

COMPETING INTERESTS

Authors have declared that no competing interests exist.

REFERENCES

1. von Arx T, Friedli M, Sendi P, Lozanoff S, Bornstein MM. Location and dimensions of the mental foramen: A radiographic analysis by using cone-beam computed tomography. *J Endod.* 2013 Dec;39(12): 1522–8.
2. Muineo-Lorenzo J, Fernández-Alonso A, Smyth-Chamosa E, Suárez-Quintanilla JA, Varela-Mallou J, Suárez-Cunqueiro MM. Predictive factors of the dimensions and location of mental foramen using cone beam computed tomography [Internet]. *Plos One.* 2017;12:e0179704. Available: <http://dx.doi.org/10.1371/journal.pone.0179704>
3. Chikkanarasaiah N, Krishnamurthy NH, Vathariparambath N. Morphological Location of Mandibular and Mental Foramen in Teenagers: A Cone-beam Computed Tomography Study [Internet]. *Journal of Health Sciences & Research.* 2020;11:1–5. Available: <http://dx.doi.org/10.5005/jp-journals-10042-1088>
4. Shruthi M, Preetha S. Effect of Simple Tongue Exercises in Habitual Snorers [Internet]. *Research Journal of Pharmacy and Technology.* 2018;11:3614. Available: <http://dx.doi.org/10.5958/0974-360x.2018.00665.0>
5. Preetha S, Packyanathan J. Comparison of the effect of Yoga, Zumba and Aerobics in controlling blood pressure in the Indian population [Internet]. *Journal of Family Medicine and Primary Care.* 2020;9:547. Available: http://dx.doi.org/10.4103/jfmpc.jfmpc_607_19
6. J SK, Saveetha Dental College and Hospitals, Road PH, Chennai, Tamilnadu, Preetha S, et al. Effect of aerobics exercise and yoga on blood pressure in hypertensives [Internet]. *International Journal of Current Advanced Research.* 2017;6:3124–6. Available: <http://dx.doi.org/10.24327/ijcar.2017.3126.0200>
7. Prathap L, Suganthirababu P, Ganesan D. Fluctuating Asymmetry of Dermatoglyphics and DNA Polymorphism in Breast Cancer Population [Internet]. *Indian Journal of Public Health Research and Development.* 2019;9:3574. Available: <http://dx.doi.org/10.5958/0976-5506.2019.04141.x>
8. Lavanya J, Prathap S, Alagesan J. Digital and palmar dermal ridge patterns in population with breast carcinoma. *Biomedicine.* 2014 Jul 1;34(3): 315–21.
9. Prathap L, Jagadeesan V. Association of quantitative and qualitative dermatoglyphic variable and DNA polymorphism in female breast cancer population. *Online J Health [Internet];* 2017. Available: https://www.researchgate.net/profile/Prathap_Suganthirababu/publication/321606278_Association_of_Quantitative_and_Qualitative_Dermatoglyphic_Variable_and_DNA_Polymorphism_in_Female_Breast_Cancer_Population/links/5a28c8f1a6fdcc8e8671c0cd/Association-of-Quantitative-and-Qualitative-Dermatoglyphic-Variable-and-DNA-Polymorphism-in-Female-Breast-Cancer-Population.pdf
10. Lavanya J, Kumar VJ, Sudhakar N, Prathap S. Analysis of DNA repair genetic polymorphism in breast cancer population. *Int J Pharma Bio Sci [Internet];* 2015. Available: https://scholar.google.ca/scholar?cluster=8949053652564257518&hl=en&as_sdt=0,5&scioldt=0,5
11. Prathap L, Suganthirababu P. Estrogen Exposure and Its Influence in DNA Repair Genetic Variants in Breast Cancer Population [Internet]. *Biomedical and Pharmacology Journal.* 2020;13:1321–7. Available: <http://dx.doi.org/10.13005/bpj/2001>
12. Ravikumar H, Prathap L, Preetha S. Analysis of Palmar ATD Angle in Population with Malocclusion. 2020 Jan 1;1174–82.
13. Prathap L. Interplay of oxidative stress and lipoproteins in breast carcinoma initiation, promotion and progression -A systematic review. *PalArch's Journal of Archaeology of Egypt/ Egyptology [Internet].* 2021 Jan 7 [cited 2021 Mar 9];17(7). Available: <http://dx.doi.org/>
14. Zhang L, Zheng Q. Anatomic Relationship between Mental Foramen and Peripheral Structures Observed By Cone-Beam Computed Tomography [Internet]. *Anatomy & Physiology.* 2015;05. Available: <http://dx.doi.org/10.4172/2161-0940.1000182>
15. Sekar D, Lakshmanan G, Mani P, Biruntha M. Methylation-dependent circulating microRNA 510 in preeclampsia patients. *Hypertens Res.* 2019 Oct;42(10):1647–8.

16. Princeton B, Santhakumar P, Prathap L. Awareness on Preventive Measures taken by Health Care Professionals Attending COVID-19 Patients among Dental Students. *Eur J Dent.* 2020 Dec;14(S 01):S105–9.
17. Logeshwari R, Rama Parvathy L. Generating logistic chaotic sequence using geometric pattern to decompose and recombine the pixel values. *Multimed Tools Appl.* 2020 Aug;79(31-32):22375–88.
18. Johnson J, Lakshmanan G, M B, R M V, Kalimuthu K, Sekar D. Computational identification of MiRNA-7110 from pulmonary arterial hypertension (PAH) ESTs: A new microRNA that links diabetes and PAH. *Hypertens Res.* 2020 Apr;43(4):360–2.
19. Paramasivam A, Priyadharsini JV, Raghunandhakumar S, Elumalai P. A novel COVID-19 and its effects on cardiovascular disease. *Hypertens Res.* 2020 Jul;43(7):729–30.
20. Pujari GRS, Subramanian V, Rao SR. Effects of *Celastrus paniculatus* Willd. and *Sida cordifolia* Linn. in Kainic Acid Induced Hippocampus Damage in Rats. *Ind J Pharm Educ.* 2019 Jul 3;53(3):537–44.
21. Rajkumar KV, Lakshmanan G, Sekar D. Identification of miR-802-5p and its involvement in type 2 diabetes mellitus. *World J Diabetes.* 2020 Dec 15; 11(12):567–71.
22. Ravisankar R, Jayaprakash P, Eswaran P, Mohanraj K, Vinitha G, Pichumani M. Synthesis, growth, optical and third-order nonlinear optical properties of glycine sodium nitrate single crystal for photonic device applications. *J Mater Sci: Mater Electron.* 2020 Oct;31(20):17320–31.
23. Wu S, Rajeshkumar S, Madasamy M, Mahendran V. Green synthesis of copper nanoparticles using *Cissus vitifolia* and its antioxidant and antibacterial activity against urinary tract infection pathogens. *Artif Cells Nanomed Biotechnol.* 2020 Dec;48(1):1153–8.
24. Vikneshan M, Saravanakumar R, Mangaiyarkarasi R, Rajeshkumar S, Samuel SR, Suganya M, et al. Algal biomass as a source for novel oral nano-antimicrobial agent. *Saudi J Biol Sci.* 2020 Dec;27(12):3753–8.
25. Alharbi KS, Fuloria NK, Fuloria S, Rahman SB, Al-Malki WH, Javed Shaikh MA, et al. Nuclear factor-kappa B and its role in inflammatory lung disease. *Chem Biol Interact.* 2021 Aug 25;345:109568.
26. Rao SK, Kalai Priya A, Manjunath Kamath S, Karthick P, Renganathan B, Anuraj S, et al. Unequivocal evidence of enhanced room temperature sensing properties of clad modified Nd doped mullite Bi₂Fe₄O₉ in fiber optic gas sensor [Internet]. *Journal of Alloys and Compounds.* 2020;838: 155603. Available: <http://dx.doi.org/10.1016/j.jallcom.2020.155603>
27. Bhavikatti SK, Karobari MI, Zainuddin SLA, Marya A, Nadaf SJ, Sawant VJ, et al. Investigating the Antioxidant and Cytocompatibility of *Mimusops elengi* Linn Extract over Human Gingival Fibroblast Cells. *Int J Environ Res Public Health* [Internet]. 2021 Jul 4;18(13). Available: <http://dx.doi.org/10.3390/ijerph18137162>
28. Marya A, Karobari MI, Selvaraj S, Adil AH, Assiry AA, Rabaan AA, et al. Risk Perception of SARS-CoV-2 Infection and Implementation of Various Protective Measures by Dentists Across Various Countries. *Int J Environ Res Public Health* [Internet]. 2021 May 29;18(11). Available: <http://dx.doi.org/10.3390/ijerph18115848>
29. Barma MD, Muthupandian I, Samuel SR, Amaechi BT. Inhibition of *Streptococcus mutans*, antioxidant property and cytotoxicity of novel nano-zinc oxide varnish. *Arch Oral Biol.* 2021 Jun;126:105132.
30. Vijayashree Priyadharsini J. In silico validation of the non-antibiotic drugs acetaminophen and ibuprofen as antibacterial agents against red complex pathogens. *J Periodontol.* 2019 Dec;90(12):1441–8.
31. Priyadharsini JV, Vijayashree Priyadharsini J, Smiline Girija AS, Paramasivam A. In silico analysis of virulence genes in an emerging dental pathogen *A. baumannii* and related species [Internet]. *Archives of Oral Biology.* 2018;94:93–8. Available: <http://dx.doi.org/10.1016/j.archor.2018.07.001>
32. Uma Maheswari TN, Nivedhitha MS, Ramani P. Expression profile of salivary micro RNA-21 and 31 in oral potentially malignant disorders. *Braz Oral Res.* 2020 Feb 10;34:e002.

33. Gudipani RK, Alam MK, Patil SR, Karobari MI. Measurement of the Maximum Occlusal Bite Force and Its Relation to the Caries Spectrum of First Permanent Molars in Early Permanent Dentition. *J Clin Pediatr Dent.* 2020 Dec 1;44(6):423–8.
34. Chaturvedula BB, Muthukrishnan A, Bhuvanaraghan A, Sandler J, Thiruvengkatachari B. Dens invaginatus: a review and orthodontic implications. *Br Dent J.* 2021 Mar;230(6):345–50.
35. Rajkohila J, Daniel P, Ambikaipakan S, Rabi S. Morphological and morphometric analysis of accessory mental foramen in dry human mandibles of south indian population. *Indian J Dent Res.* 2018 Jan;29(1):56–60.
36. Daniel P, Rajkohila J, Ambikaipakan S, Rabi S. Morphological and morphometric analysis of accessory mental foramen in dry human mandibles of south indian population [Internet]. *Indian Journal of Dental Research.* 2018;29:56. Available:http://dx.doi.org/10.4103/ijdr.ijdr_146_17
37. Suman P, Singh S, Mahato RK. Mental foramen and accessory mental foramen: a dry human mandibles study in South Indian population [Internet]. *National Journal of Clinical Anatomy.* 2018;7:182–91. Available:<http://dx.doi.org/10.1055/s-0040-1701734>
38. Pyun J-H, Lim Y-J, Kim M-J, Ahn S-J, Kim J. Position of the mental foramen on panoramic radiographs and its relation to the horizontal course of the mandibular canal: A computed tomographic analysis [Internet]. *Clinical Oral Implants Research.* 2013;24:890–5. Available:<http://dx.doi.org/10.1111/j.1600-0501.2011.02400.x>
39. Laher AE. The Ultrasonographic Determination of the Position of the Mental Foramen and Its Relation to the Mandibular Premolar Teeth [Internet]. *Journal of Clinical and Diagnostic Research;* 2016. Available:<http://dx.doi.org/10.7860/jcdr/2016/18808.7992>
40. Sultana Z, Professor A, Department of Anatomy, Shadan institute of medical sciences, Hyderabad, Telangana, et al. A morphometric study of mandibular foramen in dry adult human mandibles of Indian population in Telangana State [Internet]. *International Journal of Anatomy and Research.* 2019;7:7080–5. Available:<http://dx.doi.org/10.16965/ijar.2019.308>
41. Aminoshariae A, Su A, Kulild JC. Determination of the location of the mental foramen: a critical review. *J Endod.* 2014 Apr;40(4):471–5.
42. Zmyslowska-Polakowska E, Radwanski M, Ledzion S, Leski M, Zmyslowska A, Lukomska-Szymanska M. Evaluation of Size and Location of a Mental Foramen in the Polish Population Using Cone-Beam Computed Tomography. *Biomed Res Int.* 2019 Jan 2;2019:1659476.
43. Guo JL, Su L, Zhao JL, Yang L, Lv DL, Li YQ, et al. Location of Mental Foramen Based on Soft- and Hard-Tissue Landmarks in a Chinese Population [Internet]. *Journal of Craniofacial Surgery.* 2009;20:2235–7. Available:<http://dx.doi.org/10.1097/scs.0b013e3181bf85f4>
44. Voljevic A, Talović E, Hasanović A. Morphological and morphometric analysis of the shape, position, number and size of mental foramen on human mandibles. *Acta Med Acad.* 2015;44(1):31–8.
45. Ghaffari R, Afghari P, Sohailpour S. Anatomical assessment of foramen tympanicum using cone beam computed tomography images [Internet]. *Dental Hypotheses.* 2016;7:107. Available:<http://dx.doi.org/10.4103/2155-8213.190486>
46. Ajmal M. Evaluation of Mental Foramen Position from Panoramic Dental Radiographs [Internet]. *The Journal of Contemporary Dental Practice.* 2014;15:399–402. Available:<http://dx.doi.org/10.5005/jp-journals-10024-1551>

© 2021 Ashwin and Prathap; This is an Open Access article distributed under the terms of the Creative Commons Attribution License (<http://creativecommons.org/licenses/by/4.0/>), which permits unrestricted use, distribution, and reproduction in any medium, provided the original work is properly cited.

Peer-review history:
The peer review history for this paper can be accessed here:
<https://www.sdiarticle5.com/review-history/78958>