



E-Cadherin as a Marker for Nodal Metastasis in Head and Neck Squamous Cell Carcinoma

**Saima Akram Butt¹, Anwar Ali², Lubna Avesi², Shoaib Khan^{1*},
Tazeen Mustansir² and Talat Mirza¹**

¹Ziauddin University, 4/8 Shahra e Galib, Clifton Block 6, Karachi, Pakistan.

²Dow University of Health Sciences, Ojha Campus, Gulistan e Hijri, Safora Goth, Karachi, Pakistan.

Authors' contributions

This work was carried out in collaboration among all authors. All authors read and approved the final manuscript.

Article Information

DOI: 10.9734/JAMMR/2019/v29i930127

Editor(s):

(1) Dr. Thomas I. Nathaniel, University of South Carolina, School of Medicine-Greenville, Greenville, USA.

Reviewers:

(1) Francesca Gorini, National Research Council, Italy.

(2) Vijaya Krishnan, Maharashtra University of Health Sciences, India.

Complete Peer review History: <http://www.sdiarticle3.com/review-history/49111>

Original Research Article

Received 28 February 2019

Accepted 08 May 2019

Published 17 May 2019

ABSTRACT

Aim: Head and neck cancers, all over the world, contribute greatly to the number of deaths, despite the advancements in the therapeutic strategies. It is characterized by locoregional disease with a tendency for metastasis to the cervical lymph nodes. The pre-operative detection of lymph node metastasis is critical for the effective treatment of patients with head and neck squamous cell carcinoma. Therefore the objective of this study was to identify E-cadherin as a marker for prediction of lymph node metastasis in head and neck squamous cell carcinoma (HNSCC).

Study Design: Cross-sectional study.

Place and Duration of Study: Dow University of Health Sciences, Karachi. 1 Year duration.

Methodology: Cross-sectional analysis of 54 subjects with HNSCC, who underwent neck dissections, was carried out. Expression of E-cadherin was evaluated using immunohistochemical analysis and traditional histological parameters, and correlation of E-Cadherin with histologically verified presence of regional metastases was determined. Data was subjected to descriptive statistics and chi-square using Spss v.16.0.

Results: 54 patients included 33 males (61.1%) and 21 females (38.9%) aged from 18 to 73 (mean 44.8±12.7). A statistically significant relationship between the Downregulation of E-cadherin

*Corresponding author: E-mail: shoaib.khan@zu.edu.pk;

and histologically verified presence of nodal metastasis was established. (p value= 0.01).

Conclusion: This study shows that low E-cadherin expression is useful for predicting lymph node metastases in cases of head and neck carcinoma.

Keywords: E-cadherin; cancer; neoplasm; metastasis; lymph node.

1. INTRODUCTION

Oral squamous cell carcinoma (OSCC) is ranked as the sixth most widespread malignant tumor worldwide illustrated by loco-regional disease with a predisposition for metastasis to the cervical lymph nodes.[1] Despite the recent improvements in surgical and adjuvant chemoradiotherapy, the occurrence and mortality from OSCC has shown a steady increase in several countries, and thus the 5-year survival rate of 50% has failed to improve over the past few decades.[2, 3] In Pakistan, there are no complete and comprehensive databases available concerning any disease including cancer, and therefore the only data that exists is hospital based.[4] WHO estimated that the death rate worldwide per 100,000 population is 7.3.[5] In Sindh, the prevalence of head and neck cancers is 22.6%, which is the highest amongst all the provinces. Punjab takes second place with a prevalence of 13.4%. Baluchistan and North West Frontier Province (NWFP) accounted for 11.4% and 8.6% HNSCC prevalence respectively.[6] One of the earliest features of tumor-cell dissemination in most human carcinomas is the metastasis via lymph nodes.[7] One of the key phenomenon's in metastasis is the change occurring in the cellular adhesion. [7, 8] Deterioration of the adhesion between the cells as well as that between the cell and the extracellular matrix adhesion is clearly essential for metastasis of the cancerous cells.[8] In tumors of epithelial origin, the cell – cell adhesion is chiefly regulated by the cadherin molecules especially the E- cadherins. It has been established that down regulation of the E-cadherin gene is linked with poorly differentiated type of cancers, invasion and metastasis in a range of various kinds of cancer.[8]

Detection of lymph node metastasis, preoperatively is very critical in providing effective treatment to patients who have head and neck squamous cell carcinoma. [9] Cervical lymph node metastasis cannot always be foretold from the size and the extent of primary tumor invasion [9] and simply the fact that metastases needs to attain a certain size before they become detectable (3mm) [8]. Despite the recent

advancements in the techniques of CT scan, MRI, ultrasonography, PET scan and ultrasound guided FNA biopsy, their sensitivity in detecting occult metastasis has only reached 80% and therefore the detection of occult, microscopic metastasis continues to elude true recognition, because of which the true lymph node status of the neck remains doubtful.[9] Consequently, as a result of these limitations many head and neck surgeons perform radical or selective type of neck dissection. This results in about 80% of the patients with N0 disease-receiving treatment that is unnecessary accompanied by concomitant morbidity.[8]

2. METHODS

A Cross-sectional analysis of 54 subjects with head and neck squamous cell carcinoma, who underwent neck dissections, in the Ear, Nose and Throat (ENT) ward at Civil Hospital, was carried out. Clinically diagnosed patients, of all ages, including both genders that were undergoing neck dissections due to HNSCC were included in the study whereas patients with odontogenic and non-odontogenic tumors of the oral cavity and those who failed to sign a consent form were excluded from the study. The histopathological grade was determined according to the degree of differentiation of the tumor (Broders'Classification).[10] Tumors were staged according to the American Joint Committee on Cancer (AJCC) TNM classification 7th edition.[11] Expression of E-cadherin was evaluated using conventional histopathological grading parameters and immunohistochemical examination, and the relationship of E-Cadherin with the occurrence of local metastases was determined. The data was subjected to descriptive statistics and chi square using SPSS V.16.0.

Enzyme immunoassays (EIA), including enzyme linked immunosorbant assays (ELISA), are used to detect antigens of infectious agents present in clinical specimens. One commonly used format is to bind a captured antibody, specific for the antigen in question, to the wells of plastic micro dilution trays. The specimen containing the antigen is incubated in the wells followed by

washing of the wells by a second antibody for the antigen labeled with enzyme to detect the antigen. Addition of the substrate for the enzyme allows detection of the bound antigen by colorimetric reaction. Rabbit monoclonal antibody was used against E-cadherin (EP700Y, cell marquee and diluted 1:50). Analysis for the immunoreactivity of the antibodies is then performed under light microscopy.

E-cadherin immunolabeling was regarded as positive when the membrane of the cytoplasm stained.[12] A semi-quantitative assessment was carried out by counting the proportion of positive neoplastic cells in 10 different fields under 40X magnification. Immunohistochemical values for E-Cadherin below or equal to 50% of positive cells were considered as "low expression". Values greater than 50% were regarded as "high expression".[12] This was done in order to be consistent with the criterion used in the formerly published literature.[12-14] Immunohistochemical evaluation was performed by two researchers (L.A., S.A.B.). For cases that had different scores, an agreement was reached by discussing the cases.

3. RESULTS

Out Of the 54 patients 33(61.1%) were males and 21 (38.9%) were females hence showing a male preponderance. The main clinical characteristics of the patients analyzed in this study are detailed in Table 1. The mean age of the patients was 44.8 ± 12.7 and an age range of 18-73. Most common age of patients presenting with HNSCC was 40 years. Tongue was the most frequently involved site. 17 out of 54 patients presented with squamous carcinoma of the tongue. On histological examination the tumor was Well differentiated in 17 (31.5%) of patients. 34 (63%) of patients, both males and females, presented with moderately differentiated carcinomas Only 3 cases of Poorly differentiated squamous cell carcinomas were received. TNM staging system as specified by the AJCC was used to categorize tumor size and regional nodal involvement. 12 patients (22.2%) had T1 disease, 15 (27.8%) T2, 9 (16.7%) t3 and T4a was the most common found in 18(33.3%). The AJCC staging system was also used to categorize regional nodal involvement. 16 (29.6%) patients were staged N0; 9 (16.7%) N1, 3 (5.6%) N2 and 26 (48.1%) N2b (pathologic staging). 38 (70.4%) out of 54 patients showed histologically verified presence of metastasis on H&E staining, however 16 (29.6%) patients who

underwent neck dissections didn't show any metastasis. All 54 samples were successfully evaluated by immunohistochemistry staining. E-Cadherin staining showed high expression in 19 cases (35.2%) and low expression in 35 cases (64.8%). A strong statistically significant relationship was found between E-Cadherin down regulation and histologically verified presence of nodal metastasis (P Value = 0.01). In our study lower expression of E-cadherin was significantly associated with gender, the nodal status of the patient (N0 or N+) and the histologically verified presence or absence of metastasis. However, no correlation was found between the expression of E-cadherin and age, T-stage of the disease and the histological grade of the cancer. (Table 1)

4. DISCUSSION

In HNSCC, single handedly the most significant factor that can predict the prognosis is the occurrence of nodal metastasis.[15] In spite of all the extensive research carried out, in clinical practice, the difficulty to correctly and aptly detect the incidence of lymph node metastasis in patients with HNSCC remained.[16] The ability to identify the molecular markers from a primary sample of the tumor biopsy that predicts cervical node metastasis would facilitate the selection of patients at risk of nodal metastasis.[15]

The current study shows a male preponderance (61%) in contrast to the 38.9% female patients included in the study. These results are consistent with the literature reviewed.[15, 17-22] In industrialized nations, males are affected two to three times more in comparison to the females mostly due to an increased use of tobacco and alcohol.[8] In developing countries betel quid chewing and malnutrition are additional risk factors.[9] Thus prevalence is strongly influenced by ethnic background due to diverse cultural and social practices as well as diversity in the socioeconomic status.[8] This study shows that the head and neck cancer is a disease more prevalent in the fourth to fifth decade. The literature shows a slight difference, whereby the fifth and the sixth decade are more common.[12, 17, 18, 22] Our study indicated that tongue was the most common site in this series. The results are similar in some studies [21, 22] whereas they differ in other studies.[18] This difference could be explained by the simple fact that the ethnic background, nutritional status, risk factors and habits including pan, areca nut and tobacco use differ from region to region.

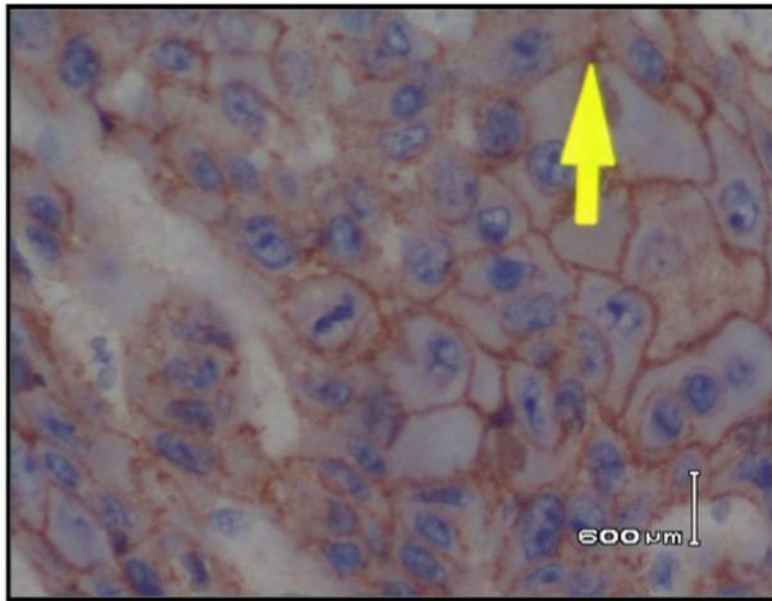


Fig 1. High expression of E-cadherin

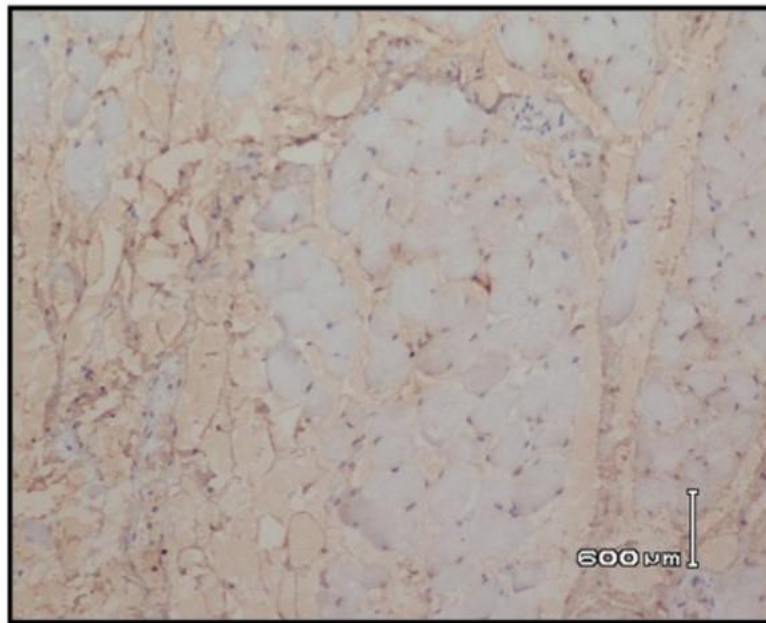


Fig. 2. Low expression of E-cadherin

A study analyzed the clinicopathologic significance of E-cadherin expression amongst 80 patients who had laryngeal squamous cell cancer. Their results suggested that expression of E-cadherin was an independent predictor of lymph node metastases.[15] The results of our study also signifies that the expression of E-

cadherin serves as an independent lymph node metastasis predictor, thus the results of our study are consistent with the findings of the study. A research conducted in China studied 150 cases of oral squamous cell carcinoma and investigated the immunoeexpression of adhesion molecules in the primary tumor tissue as well as

Table 1. The correlation of E-cadherin expression with clinico-pathologic parameters

Variables	Number of patients	E-cadherin expression		p-value
		low	High	
Sex				
Male	33	16	17	0.002
Female	21	19	2	
Age (years)				
≤60	49	31	18	0.455
>60	5	1	4	
T classification				
T1 & T2	27	18	9	0.776
T3 & T4	27	17	0	
N Status				
N0	16	0	16	0.000
N+	38	35	3	
Histological grade				
Grade 1	17	11	6	0.991
Grade 2 & 3	37	24	13	
Metastasis				
Yes	38	35	3	0.000
No	16	0	16	

Table 2. Demographics

	Males	Females
Age group	39-48	49-58
Gender	33	21
Type of cancer		
Buccal Mucosa with mandible	5	7
Buccal Mucosa	11	4
Tongue	11	6
Angle of the mouth	2	1
Lip	3	2
Floor of the mouth	1	1

lymph nodes. The study indicated the decreasing degree of immunostaining for E-cadherin with lymph node metastasis.[23] The results of our study also showed that the immunostaining intensity for E-cadherin was decreased in cases that showed histological presence of metastasis. In a group of 83 patients with oral carcinoma, a link was found between low levels of E-cadherin expression and positive outcome.[22] In a series of 58 patients, immunostaining of the E-cadherin molecule demonstrated a statistically important association with the manifestation of nodal metastases at the time of disease presentation. The overall number of lymph node metastases was associated to low E-cadherin expression in 76% of the cases and hence the result was statistically significant ($p < 0.01$).[12] A study involving a group of 45 people revealed that the huge bulk of metastatic deposits had decreased expression of E-cadherin together with their

counterparts in primary lesions.[18] In a series of 131 patients in Japan, it was observed that the expression of E-cadherin decreased with the loss of differentiation in primary carcinomas, and that lymph node metastases expressed a lower level of the protein, suggesting an important role of cadherin loss in the metastatic process.[24] The results of our study are consistent with the findings of the above mentioned studies. study involving 47 oral cavity samples, observed that lymph node metastases expressed a lower level of the protein E-cadherin in comparison to the non- metastatic counterparts.[21] In our study, we reviewed 54 samples of oral cavity and the lymph nodes and it was observed that the samples that showed histologically verified presence of metastasis showed a lower expression of E-cadherin in contrast to the samples that didn't show metastasis.

However, various studies have been unsuccessful in establishing a relationship between the expression of E-cadherin and the clinicopathological variables. In a research, the markers that are related to the invasion of the tumor as well as metastasis in 59 patients who had hypo pharyngeal and laryngeal squamous cell carcinomas with nodal metastasis were studied.[25] This study failed to ascertain a relationship between the immunolabeled tumor cells and lymph node metastasis. Another study inspected the histological features and biological markers in 31 patients. Interestingly, from all the markers that were examined immunohistochemically, E-cadherin was not relevant to the prediction of lymph node metastasis.[26] Several explanations can be suggested for conflicting results reported in previous studies about clinical importance of altered expression of E-cadherin. The location and number of analyzed cases, selection of tumors (grade and the stage of the tumor), variations in surgical method applied (extent of lymph node dissection), and variations in the evaluation of staining may independently or in

combination be responsible.[15] Zhu *et al* in his systematic review reported that E-Cadherin could be a critical factor in predicting the prognosis of Laryngeal Squamous Cell Carcinoma (LSCC).[27] A downregulation in the E- Cadherin expression in patients with LSCC was reported by Nardi *et al* and signifies its prognostic importance in cervical metastasis.[28]

A comparison of main characteristics of the studies included in literature review with the present study are highlighted in Table 3.

A few limitations of the study include: 1) Since the research was carried out in a laboratory set up, we were unable to follow up the patients in terms of effectiveness of the treatment and mortality rate, 2) financial constraints inhibited us to carry out the research at a larger scale, 3) comparable data in terms of associations and meta-analysis are extremely hard to achieve because of the diverse approaches and assessment measures used for E-cadherin.

Table 3. Comparison of main characteristics of the studies included in literature review with the present study

	Year	Patient sources	No. of patients	Clinical stages	Primary location	p. value
Zvrko et al76	2012	Montenegro	80	I-IV	Larynx	0.02
Zou et al 95	2010	China	150	I-IV	Larynx	0.000
Liu et al 90	2010	China	83	I-IV	Oral cavity	0.016
Foschini et al73	2008	Italy	58	I-IV	Oral cavity	0.01
Rodrigo et al14	2007	Spain	95	I-IV	Larynx	0.006
Ueda et al96	2006	Japan	131	I-IV	Oral cavity	0.013
Hung et al89	2006	Taiwan	45	I-IV	Oral cavity	0.003
Kurtz et al74	2006	USA	45	I-IV	Head neck	0.004
Dinis- Friettas et al91	2006	Spain	47	I-IV	Oral cavity	0.000
Lim et al 92	2005	South Korea	84	I-IV	Oral cavity	0.02
Bosch et al 93	2005	Germany	151	I-IV	Head neck	0.000
Nakanishi et al97	2004	Japan	91	I-IV	Tongue	0.053
Present study	2013	Pakistan	54	I-IV	Oral cavity	0.000

5. CONCLUSION

To conclude, our findings, together with the facts available in the literature, present convincing data for the prognostic effect of E-cadherin expression. This suggests that the immunohistochemical establishment of E-cadherin expression gives us a tool to characterize the potential of oral cancers to metastasize. This is why the expression of E-cadherin may play a pivotal role while making a choice to treat a N0 neck either with a neck dissection or keeping the patient on a close follow up.[15]

CONSENT

The participants were explained the whole procedure and a consent form was signed. The participants were also informed that their samples will not be used for any other purpose but research and that their names and details will be kept confidential.

ETHICAL APPROVAL

The study was approved by the Institutional Review Board of the Dow University of Health Sciences via letter no IRB-291/ DUHS-11.

ACKNOWLEDGEMENT

I would like to acknowledge DOW University of Health Sciences for giving us a financial grant to conduct this research. I would also like to thank Dr. Mehwish Hussain for her constant help in the statistics and results of this study.

CONFLICT OF INTEREST

A Research grant was awarded by the Dow University of Health Sciences for conducting this research.

REFERENCES

1. Warnakulasuriya S. Global epidemiology of oral and oropharyngeal cancer. *Oral oncology*. 2009;45(4-5):309-16.
2. Jemal A, Siegel R, Ward E, Hao Y, Xu J, Murray T, et al. *Cancer statistics, 2008*. CA: A cancer journal for clinicians. 2008;58(2):71-96.
3. Bagan JV, Scully C. Recent advances in Oral Oncology 2007: Epidemiology, aetiopathogenesis, diagnosis and prognostication. *Oral oncology*. 2008; 44(2):103-8.
4. Hanif M, Zaidi P, Kamal S, Hameed A. Institution-based cancer incidence in a local population in Pakistan: nine year data analysis. *Asian Pacific Journal of Cancer Prevention : APJCP*. 2009;10(2):227-30.
5. WHO. WHO estimated death rates 2004 by region; 2004. [10-07-2015]. Available:<http://www.who.int/countries/pak/en/>.
6. Chaudhry S, Khan AA, Mirza KM, Iqbal HA, Masood Y, Khan NR, et al. Estimating the burden of head and neck cancers in the public health sector of Pakistan. *Asian Pacific Journal of Cancer Prevention: APJCP*. 2008;9(3):529-32.
7. Van Trappen PO, Pepper MS. Lymphatic dissemination of tumour cells and the formation of micrometastases. *The Lancet Oncology*. 2002;3(1):44-52.
8. Takes RP, Rinaldo A, Rodrigo JP, Devaney KO, Fagan JJ, Ferlito A. Can biomarkers play a role in the decision about treatment of the clinically negative neck in patients with head and neck cancer? *Head & neck*. 2008;30(4):525-38.
9. Rodrigo JP, Dominguez F, Suarez V, Canel M, Secades P, Chiara MD. Focal adhesion kinase and E-cadherin as markers for nodal metastasis in laryngeal cancer. *Archives of otolaryngology-head & neck surgery*. 2007;133(2):145-50.
10. Neena D, Siddharth S, Keyuri P, Munira J. Histological grading of oral cancer: A comparison of different systems and their relation to lymph node metastasis. *National Journal of Community Medicine*. 2011;2(1): 136-42.
11. Edge SB, Compton CC. The American Joint Committee on Cancer: the 7th Edition of the AJCC Cancer Staging Manual and the Future of TNM. *Annals of Surgical Oncology*. 2010;17(6):1471-4.
12. Foschini MP, Cocchi R, Morandi L, Marucci G, Pennesi MG, Righi A, et al. E-cadherin loss and ΔNp73L expression in oral squamous cell carcinomas showing

- aggressive behavior. *Head & neck*. 2008; 30(11):1475-82.
13. Kurtz KA, Hoffman HT, Zimmerman MB, Robinson RA. Decreased E-Cadherin but not β -Catenin Expression is Associated with Vascular Invasion and Decreased Survival in Head and Neck Squamous Carcinomas. *Otolaryngology-Head and Neck Surgery*. 2006;134(1):142-6.
 14. Lim SC, Zhang S, Ishii G, Endoh Y, Kodama K, Miyamoto S, et al. Predictive markers for late cervical metastasis in stage I and II invasive squamous cell carcinoma of the oral tongue. *Clinical cancer research : An Official Journal of the American Association for Cancer Research*. 2004;10(1 Pt 1):166-72.
 15. Zvrko E, Mikić A, Jančić S. Relationship of E-cadherin with cervical lymph node metastasis in laryngeal cancer. *Collegium antropologicum*. 2013;36(2):119-24.
 16. Zhao Z, Ge J, Sun Y, Tian L, Lu J, Liu M, et al. Is E-cadherin immunoeexpression a prognostic factor for head and neck squamous cell carcinoma (HNSCC)? A systematic review and meta-analysis. *Oral oncology*. 1995;48(9):761-7.
 17. Kurtz KA, Hoffman HT, Zimmerman MB, Robinson RA. Decreased E-cadherin but not beta-catenin expression is associated with vascular invasion and decreased survival in head and neck squamous carcinomas. *Otolaryngology--head and neck surgery : Official Journal of American Academy of Otolaryngology-Head and Neck Surgery*. 2006;134(1):142-6.
 18. Hung KF, Chang CS, Liu CJ, Lui MT, Cheng CY, Kao SY. Differential expression of E-cadherin in metastatic lesions comparing to primary oral squamous cell carcinoma. *Journal of oral pathology & medicine : Official publication of the International Association of Oral Pathologists and the American Academy of Oral Pathology*. 2006;35(10):589-94.
 19. Bosch FX, Andl C, Abel U, Kartenbeck J. E-cadherin is a selective and strongly dominant prognostic factor in squamous cell carcinoma: A comparison of E-cadherin with desmosomal components. *International Journal of Cancer*. 2005; 114(5):779-90.
 20. Lim J, Kim JH, Paeng JY, Kim MJ, Hong SD, Lee JI, et al. Prognostic value of activated Akt expression in oral squamous cell carcinoma. *Journal of Clinical Pathology*. 2005;58(11):1199-205.
 21. Diniz-Freitas M, García-Caballero T, Antúnez-López J, Gándara-Rey JM, García-García A. Reduced E-cadherin expression is an indicator of unfavourable prognosis in oral squamous cell carcinoma. *Oral oncology*. 2006;42(2):190-200.
 22. Liu LK, Jiang XY, Zhou XX, Wang DM, Song XL, Jiang HB. Upregulation of vimentin and aberrant expression of E-cadherin/beta-catenin complex in oral squamous cell carcinomas: Correlation with the clinicopathological features and patient outcome. *Modern pathology : An Official Journal of the United States and Canadian Academy of Pathology, Inc*. 2010;23(2):213-24.
 23. Zou J, Yang H, Chen F, Zhao H, Lin P, Zhang J, et al. Prognostic significance of fascin-1 and E-cadherin expression in laryngeal squamous cell carcinoma. *European journal of cancer prevention : The Official Journal of the European Cancer Prevention Organisation (ECP)*. 2010;19(1):11-7.
 24. Ueda G, Sunakawa H, Nakamori K, Shinya T, Tsuchiko W, Tamura Y, et al. Aberrant expression of beta- and gamma-catenin is an independent prognostic marker in oral squamous cell carcinoma. *Int J Oral Maxillofac Surg*. 2006;35(4):356-61.
 25. Liu M, Lawson G, Delos M, Jamart J, Chatelain B, Remacle M, et al. Prognostic value of cell proliferation markers, tumour suppressor proteins and cell adhesion molecules in primary squamous cell carcinoma of the larynx and hypopharynx. *European archives of oto-rhino-laryngology: Official journal of the European Federation of Oto-Rhino-Laryngological Societies (EUFOS) : affiliated with the German Society for Oto-Rhino-Laryngology - Head and Neck Surgery*. 2003;260(1):28-34.
 26. Takes RP, Baatenburg de Jong RJ, Schuurin E, Hermans J, Vis AA, Litvinov SV, et al. Markers for assessment of nodal metastasis in laryngeal carcinoma. *Archives of Otolaryngology--Head & Neck surgery*. 1997;123(4):412-9.

27. Zhu G-J, Song P-P, Zhou H, Shen X-H, Wang J-G, Ma X-F, et al. Role of epithelial-mesenchymal transition markers E-cadherin, N-cadherin, β -catenin and ZEB2 in laryngeal squamous cell carcinoma. *Oncology letters*. 2018;15(3):3472-81.
28. Nardi CE, Dedivitis RA, Camillo de Almeida R, de Matos LL, Cernea CR. The role of E-cadherin and beta-catenin in laryngeal cancer. *Oncotarget*. 2018; 9(53): 30199-209.

© 2019 Butt et al.; This is an Open Access article distributed under the terms of the Creative Commons Attribution License (<http://creativecommons.org/licenses/by/4.0>), which permits unrestricted use, distribution, and reproduction in any medium, provided the original work is properly cited.

Peer-review history:

The peer review history for this paper can be accessed here:
<http://www.sdiarticle3.com/review-history/49111>