

---

# Spontaneous Enlargement then Regression of a Colloid Cyst of the III Ventricle

Gillian Duncan<sup>1</sup>, Avinash Kumar Kanodia<sup>1\*</sup> and Sam El Jamel<sup>2</sup>

<sup>1</sup>X-ray Department, Ninewells Hospital, Dundee, UK.

<sup>2</sup>Department of Neurosurgery, Ninewells Hospital, Dundee, UK.

## Authors' contributions

*This work was carried out in collaboration between all authors. It was initially written by author GD with inputs and guidance from authors AKK and SEJ. All authors read and approved the final manuscript.*

Case Study

Received 3<sup>rd</sup> October 2013  
Accepted 18<sup>th</sup> November 2013  
Published 7<sup>th</sup> December 2013

---

## ABSTRACT

**Aim:** We describe a case of a 22 year old pregnant female patient who was found to have a small colloid cyst that increased spontaneously, followed by spontaneous significant reduction in size.

**Presentation of Case:** The patient's colloid cyst was picked up incidentally in late pregnancy at 39 weeks. It showed spontaneous increase in size accompanied by deterioration of symptoms at 31 months post diagnosis and then showed significant spontaneous reduction in size at 38 months post diagnosis.

**Discussion and Conclusion:** Spontaneous reduction of a colloid cyst of third ventricle is a very rarely described phenomenon. To our knowledge this is one of only 3 cases of spontaneous regression of an III ventricular colloid cyst. It may be reasonable to follow up cases, where there is a documented history of increase.

*Keywords: Colloid cyst; spontaneous reduction; III ventricle.*

## 1. INTRODUCTION

Colloid cysts are usually detected as incidental findings within anterior part of third ventricle, though can occasionally be symptomatic due to obstruction at Foramen of Monro. They

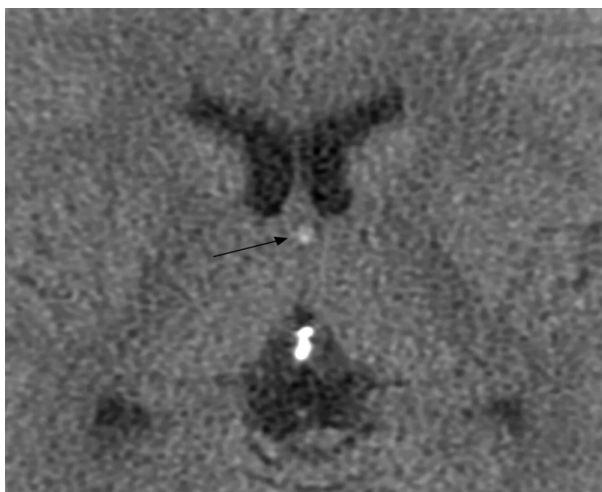---

\*Corresponding author: Email: [ak\\_kanodia@rediffmail.com](mailto:ak_kanodia@rediffmail.com);

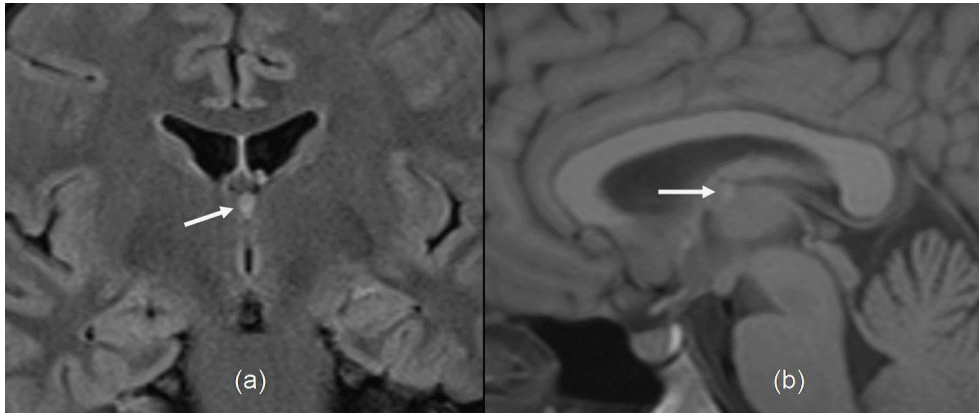
usually demonstrate no significant change in size, although can sometimes show an increase in size. However, spontaneous reduction in size is very rare. We think that the current case is only the fourth documented case of spontaneous reduction/resolution of a third ventricular colloid cyst.

## **2. PRESENTATION OF CASE**

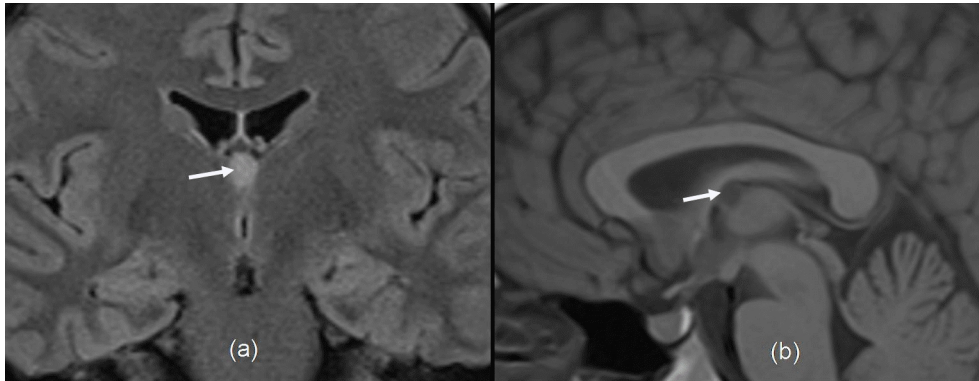
A 22 year old female patient presented at 39 weeks gestation with a 2 week history of headache. These headaches were described as left sided fronto-temporal with some associated alteration in sensation on the left side of the face. This was accompanied by altered proprioception in the right arm but no other demonstrable neurological deficit. There was no evidence of pre-eclampsia and other observations were satisfactory. A CT scan of the brain was undertaken which demonstrated no acute intra-cranial haemorrhage or infarct, but highlighted a prominent pituitary gland and 3mm hyperdense lesion in the region of the III ventricle (Fig. 1). MRI scan was undertaken to clarify the appearances in both the sellar region and III ventricle. This confirmed that the appearance of pituitary gland was physiological and also the presence of a small high T1 signal lesion adjacent to the Foramen of Munro in keeping with a 3mm colloid cyst (Fig. 2). There was no associated hydrocephalus. The venous sinuses were normal. The patient was managed conservatively. Repeat MRI scan at 12 months showed no interval change, however a further scan at 31 months showed that the lesion has increased in size from 3mm to 6mm and had also become low signal on T1 weighted images (Fig. 3). Persistent headaches were reported at this time, however there was no radiological evidence of CSF obstruction and conservative management was continued. A further MRI scan at 38 months demonstrated reduction in size of the colloid cyst to 3mm and return of the initially noted high T1 signal (Fig. 4). This resolution persisted on a final follow up scan at 50 months. The patient continues to have intermittent headache but following specialist review, a diagnosis of chronic migraine has been made.



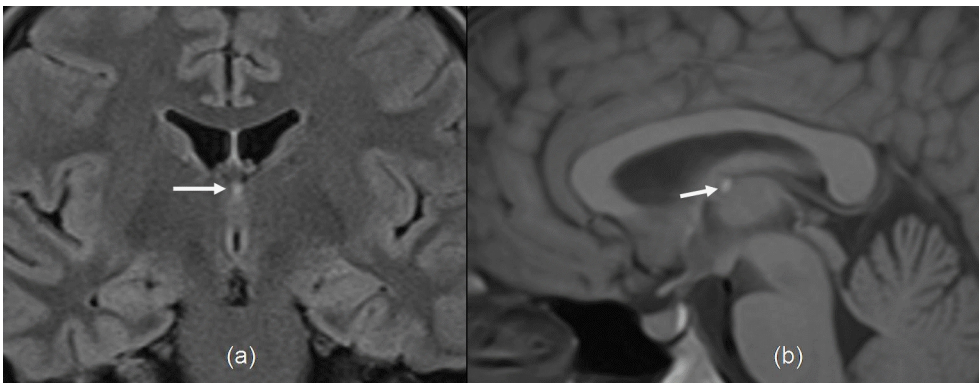
**Fig. 1. CT scan showing a small hyperdense lesion (arrow) on the anterior aspect of third ventricle near foramen of Monro**



**Fig. 2.** The initial MRI (a) FLAIR coronal and (b) T1-weighted sagittal images showing the small colloid cyst (white arrow) on the anterior aspect of third ventricle



**Fig. 3.** The follow up MRI at 31 weeks (a) FLAIR coronal and (b) T1-weighted sagittal images showing the colloid cyst (white arrow) has significantly increased in size and shows low T1 signal on (b)



**Fig. 4.** The follow up MRI at 38 weeks (a) FLAIR coronal and (b) T1-weighted sagittal images showing the colloid cyst (white arrow) has significantly decreased in size and shows high T1 signal on (b)

### **3. DISCUSSION**

Colloid cysts are benign mucin-containing cysts with more than 99% of these lesions found near the Foramen of Monro [1]. Around 3 million people per year receive a diagnosis of colloid cyst, these lesions accounting for 0.5-1% of primary brain tumours and 15-20% of intraventricular tumours [1,2]. Colloid cysts are derived from embryonic endoderm and occur when ectopic endoderm migrates into the velum interpositum during embryonic development [1]. Most commonly presenting in the 3<sup>rd</sup> to 5<sup>th</sup> decades of life, their occurrence in the paediatric population is rare [3]. Colloid cysts are histologically benign, lined up by simple stratified epithelium with interspersed mucous goblet cells and scattered ciliated cells [3]. Although often an incidental finding, patients with III ventricular colloid cysts typically present due to cerebrospinal fluid obstruction at the Foramen of Munro [4]. Typically attached to the antero-superior portion of the III ventricular roof, the lesions may be pendulous, producing symptoms depending on patient position such as a headache relieved by standing [1,3]. Other symptoms include drop attacks, progressive dementia and episodic loss of consciousness [1,3]. Rarely, even small colloid cysts may produce acute hydrocephalus with resultant brain herniation and sudden death [1].

Location is the best imaging feature of a colloid cyst, classically located near the foramen of Monro [1]. Generally a well defined, hyperdense lesion on non enhanced CT, these cysts are most commonly hyperintense on T1 weighted images and isointense on T2 weighted images [1]. Peripheral rim enhancement can be seen occasionally [3]. The imaging appearance is pathognomic, with little in a way of a differential diagnosis, the most commonly mistaken appearance is that of CSF flow artefact from turbulent flow around the Foramen of Munro in some of the MRI sequences [1].

It is proposed that colloid cysts cause symptoms secondary to rapid expansion, obstruction to the flow of CSF and resultant raised intracranial pressure with inadequate time for the patient to accommodate these changes [4]. Enlargement of colloid cysts is recognised and this may be related to the state of hydration of the cyst with a higher water content reflecting ongoing cyst expansion [1,4]. Acute haemorrhage into III ventricular colloid cysts has also been described as a cause for acute neurological deterioration in association with these lesions [5]. If a colloid cyst increases in size gradually the patient may accommodate the increased mass without obstruction to CSF flow and remain asymptomatic [4]. For symptomatic patients, treatment options include neuroendoscopic and microsurgical resection, both carrying a favourable outcome [6].

Spontaneous resolution/regression and rupture of known colloid cysts is very rarely described. On review of literature, we came across only 3 cases of spontaneous regression resolution or rupture reported previously [2,7,8]. The case described by Annamalai, et al. [2] was 5mm in size, was hyperintense on T1 and hypointense on T2 weighted images and completely resolved. The case by Motoyama et al. [7] was a visibly prominent lesion hyperdense on CT, that had isointense signal on T1 and hypointense signal on T2, that subsequently ruptured with a shriveled residual cyst. The case by Gbejuade, et al. [8] initially measured 8mm and had low signal on T2WI, subsequently regressed in size on follow up.

The exact mechanism of spontaneous regression is uncertain. Cyst rupture is not thought to be the aetiology in our case as the cyst was still present while there was no evidence of ventriculomegally or meningeal irritation from cyst contents at any time clinically or on sequential imaging. The cyst did however demonstrate altering T1 signal, appearing of lower

T1 when enlarged and higher T1 when smaller supporting the theory regarding cyst hydration, higher T1 corresponding to thick proteinaceous contents [4].

#### **4. CONCLUSION**

This case demonstrates that spontaneous regression of a III ventricular colloid cyst is possible, particularly those patients where there has been an increase previously and supports surveillance and conservative management in absence of a compelling clinical reason to intervene, in these otherwise rare and histologically benign lesions.

#### **CONSENT**

Written informed consent was obtained from the patient for publication of this case report and accompanying images.

#### **ETHICAL APPROVAL**

Not necessary for this case report.

#### **ACKNOWLEDGEMENTS**

No funding required.

#### **COMPETING INTERESTS**

Authors have declared that no competing interests exist.

#### **REFERENCES**

1. Osborne AG, Preese MT. Intracranial cysts: Radiologic-Pathologic correlation and imaging approach. *Radiology*. 2006;239:650–664.
2. Annamalai G, Lindsay KW, Bhattacharya JJ. Spontaneous resolution of a colloid cyst of the third ventricle. *BJR*. 2008;81:e20-e22.
3. Armao D, Castillo M, Chen H, Kwock L. Colloid cyst of the third ventricle: Imaging-pathologic correlation. *AJNR*. 2000;21:1470-77.
4. Pollock BE, Schreiner SA, Houston J 3<sup>rd</sup>. A theory on the natural history of colloid cysts of the thirds ventricle. *J Neurosurg*. 2000;46(5):1077-81.
5. Carrasco R, Pascual JM, Medina-Lopez D, Burdaspal-Moratilla A. Acute hemorrhage in a colloid cyst of the third ventricle: A rare cause of sudden deterioration. *Surg Neurol Int*. 2012;3:24.
6. Grondin RT, Hader W, MacRae ME, Hamilton MG. Endoscopic versus microsurgical resection of third ventricular colloid cysts. *Can J Neurol Sci*. 2007;34:197-207.
7. Motoyama Y, Hashimoto H, Ishida Y, Iida J. Spontaneous rupture of a presumed colloid cyst of the third ventricle. *Neurik Med Chir*. 2002;42:228-31.

8. Gbejuade H, Plaha P, Porter D. Spontaneous regression of a third ventricle colloid cyst. *Br J Neurosurg.* 2011;25(5):655-7.

---

© 2014 Duncan et al.; This is an Open Access article distributed under the terms of the Creative Commons Attribution License (<http://creativecommons.org/licenses/by/3.0>), which permits unrestricted use, distribution, and reproduction in any medium, provided the original work is properly cited.

*Peer-review history:*

*The peer review history for this paper can be accessed here:*

*<http://www.sciencedomain.org/review-history.php?iid=314&id=29&aid=2674>*