

Utility of p63 and Alpha Methyl Acyl CoA Racemase in the Lesions of Prostatic Mimickers: An Observational Study

ZEEL MONAJKUMAR PATEL¹, PREETI RAJEEV DOSHI², RACHANA RAVINDRA LAKHE³, PARINEETA SHELKE⁴



ABSTRACT

Introduction: Prostate adenocarcinoma is the most commonly occurring cancer in men. Differentiation of prostatic adenocarcinoma from prostatic mimickers sometimes difficult on the sole basis of histologic findings. Diagnosis of carcinoma is based on Immunohistochemistry (IHC) by negative immune reaction with p63 and positive staining with Alpha Methyl Acyl CoA Racemase (AMACR).

Aim: To evaluate the utility of p63 and AMACR in the prostatic mimickers.

Materials and Methods: In this analytical observational study, all prospective prostatic mimickers with transrectal ultrasound (TRUS) guided biopsies received in the pathology department of Bharati Vidyapeeth Medical College, Pune, India in a tertiary care hospital from July 2020 to July 2022 were studied. 70 cases were collected, studied and analysed which included 38 Transurethral Resection of the Prostate (TURP) specimens and 32 TRUS guided tissue biopsies. The Haematoxylin & Eosin (H&E) stained slides of all the cases were examined and divided into three categories-malignant (08 cases), prostatic mimickers

(53 cases) and suspicious for malignancy (09 cases). Further, these cases were subjected to IHC for p63 and AMACR. Statistical Package for Social Sciences (SPSS) version 25.0 software was used for data analysis using chi square test along with p-value.

Results: Out of the 53 cases of prostatic mimickers and 09 cases were suspicious for malignancy, 56 were positive for p63 and 06 were negative for p63. There was a statistically significant association between p63 IHC staining and the differentiation of benign cases from malignant prostatic lesions ($p < 0.001$). The sensitivity and specificity of p63 were 93.3% and 100% respectively. There were 08 cases of prostate adenocarcinoma stained with AMACR, all were positive. The sensitivity and specificity being 100%. Results revealed that there was a significant statistical association between the positive IHC staining of AMACR and prostatic adenocarcinoma ($p < 0.001$).

Conclusion: The diagnostic performance of p63 and AMACR proves to be significant in differentiating between the mimickers of prostatic lesions and adenocarcinoma. IHC is recommended to reduce diagnostic error in suspected cases.

Keywords: Adenocarcinoma, Immunohistochemistry, Prostate

INTRODUCTION

Prostate adenocarcinoma is one of the most commonly occurring cancers in men [1]. The regions with highest figures are Northern and Western Europe, Southern Africa, the Caribbean, Australia and North America [2]. Screening techniques like Prostate Specific Antigen (PSA), Ultrasonography (USG) and digital rectal examination has been increasing in Asia in older male population [3]. It is diagnosed by serum PSA levels, digital rectal examination and biopsy samples which are collected from TRUS guided needle biopsy or resected specimens (TURP chips) [4].

With the early detection of prostatic adenocarcinoma by extensive screening of men, a huge number of foci of adenocarcinoma seen in prostatic needle biopsy specimen, and it has become major challenging issue in the histopathology due to presence of various benign mimickers [5]. Sometimes, the diagnosis becomes difficult because of small focus of carcinoma, smaller size of tissue sample or due to presence of benign mimickers of adenocarcinoma which could be basal cell hyperplasia, squamous metaplasia, low grade and high grade prostatic intraepithelial neoplasia, atypical adenomatoid hyperplasia or presence of some normal anatomic structures like seminal vesicle and Cowper's gland which can cause erroneous diagnosis leading to inappropriate treatment, psychological and medicolegal consequences [6-8]. Prostatic mimickers sometimes cannot be diagnosed by histologic findings only. In few, diagnosis can be made on basis of presence or absence of basal cells. Basal cell layer is not seen in prostatic adenocarcinoma, while mimickers show presence of basal cell layer [9,10]. Patchy presence of basal cells in benign glands is the major limitation of using only negative

markers. So, negative immunostaining with p63 can be seen in a few of the cases, which does not rule out the benign glands as it may not always show positivity in the basal cells. Similarly, all AMACR negative does not rule out the positivity of being malignant, hence AMACR is very useful if used with p63 [5].

IHC marker like, p63 is helpful in the setting of prostatic mimickers [11] and alpha methyl acyl coA racemase (AMACR), an enzyme marker selectively expressed in prostate adenocarcinoma. Diagnosis of prostatic adenocarcinoma is based on negative reaction with p63 and positive reaction with AMACR [12-14]. Well differentiated adenocarcinoma cases were taken as a control for AMACR. The mimickers were not confirmed on histomorphology alone so, p63, a basal cell marker has been taken along with AMACR to differentiate between adenocarcinoma and mimicker. Aim of the study was to evaluate the utility of p63 and alpha methyl acyl CoA racemase (AMACR) in the prostatic mimickers and to differentiate the well differentiated prostatic carcinoma from its mimickers. To confirm the diagnosis, using basal cell markers such as p63 in association with AMACR have been shown to be helpful when small atypical glands are seen in routine histopathology.

MATERIALS AND METHODS

This analytical observational study, all prospective prostatic mimickers in TRUS guided biopsies, TURP specimens received in the pathology department of Bharati Vidyapeeth (DU) Medical College, Pune Maharashtra, India, at a tertiary care hospital from July 2020 to July 2022 were studied. The study was approved by Institutional Ethics Committee (IEC) letter no (BVDUMC/IEC136) dated 22 December 2020. All the relevant paraffin blocks with H&E

stained slides of prostate TRUS guided biopsies/TURP specimen with mimickers of prostatic lesions were retrieved from the database of the Department of Pathology.

Inclusion criteria: All TRUS guided and TURP specimens received in department were included in this study.

Exclusion criteria: Inadequate specimens, moderately and poorly differentiated adenocarcinomas were excluded from this study.

Total 70 cases were retrieved and studied, out of which 38 cases were TURP specimens and 32 cases were prostate needle biopsies.

Study Procedure

All the 70 cases were stained with H&E stain and were examined with further categorising the cases into 3 divisions-prostatic adenocarcinoma, mimickers and suspicious for malignancy. All the cases of each category were then subjected to IHC with p63 and AMACR.

Sections for Immunohistochemical assay were taken on poly-L-lysine coated clean glass slides. The endogenous peroxidase activity was blocked by using 0.3% hydrogen peroxide in methanol and further, the epitope retrieval was done as per manufacturer's instruction. IHC was performed by using anti AMACR antibody (Dako; Monoclonal rabbit Anti Human AMACR-clone 13H4) and a monoclonal anti p63 antibody. Normal breast tissue was taken as a control for p63 and for AMACR, tissue from Proximal tubule from kidney was taken as a control. IHC for p63 was interpreted as positive or negative. Nuclear positivity with p63 in basal cell layer was defined as positive staining and IHC with AMACR was interpreted as positive in case of circumferential or cytoplasmic finely granular staining in the prostate adenocarcinoma [15].

STATISTICAL ANALYSIS

Statistical analysis was done using SPSS software version 25. Sensitivity and specificity were calculated using Chi square test along with the p-value.

RESULTS

This study of prostatic mimickers includes 70 cases of which 8 cases (11%) were of prostate well differentiated prostate adenocarcinoma, 53 cases (76%) were prostate mimickers and 09 cases (13%) were suspicious for malignancy. Majority of mimickers and prostatic adenocarcinoma cases belonged to age group 61-70 years. The Prostate mimickers showed 06 cases of basal cell hyperplasia, 27 cases of Benign Prostatic Hyperplasia (BPH) with low grade Prostatic Intraepithelial Neoplasm (PIN), 12 cases of BPH with high grade PIN, 08 cases of squamous metaplasia [Table/Fig-1].

Prostate mimickers	Number of cases
Basal cell hyperplasia	06 (11.32%)
BPH with low grade PIN	27 (50.94%)
Squamous metaplasia	08 (15.09%)
BPH with high grade PIN	12 (22.65%)

[Table/Fig-1]: Distribution of prostate mimickers (n=53).

Out of 70 cases, 09 cases were suspicious for malignancy which were in diagnostic dilemma with well differentiated adenocarcinomas there were few cytological features such as presence of amphophilic cytoplasm, nuclear atypia, enlarged nucleoli, presence of basal cells in between and without stromal invasion due to which they could not be put in either categories of mimickers and well differentiated adenocarcinoma. IHC of the same showed six cases positive for p63, two cases AMACR positive and one case negative for both p63 and AMACR.

Out of 53 cases of prostatic mimickers and 9 cases of suspicious for malignancy, 56 cases were positive for p63 and 06 cases were negative for p63. Out of 53 cases of prostatic mimickers, 50 cases were positive for p63 and out of 9 cases of suspicious

for malignancy, 6 cases were positive for p63. There was a statistically significant association between p63 IHC staining and the differentiation of prostate mimickers with malignant prostatic lesions with p-value<0.001. The sensitivity and specificity were 93.3% and 100% respectively for p63 IHC marker with a positive predictive value and negative predictive value of 100% and 71.4% respectively [Table/Fig-2].

Results of p63 staining	Mimickers	Well differentiated adenocarcinoma	Total
Positive	56	0	56
Negative	06	8	14
Total	62	8	70

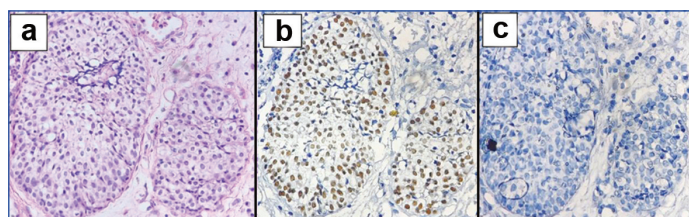
[Table/Fig-2]: Results of p63 staining in mimickers and well differentiated adenocarcinoma prostate.

08 cases of prostate adenocarcinoma were stained with AMACR and all were positive. Results revealed that there was a significant statistical association between the positive IHC staining of AMACR and prostatic well differentiated adenocarcinoma (p<0.001). The sensitivity and specificity of the biomarker AMACR were 100%. The positive predictive value and negative predictive value were 100% [Table/Fig-3].

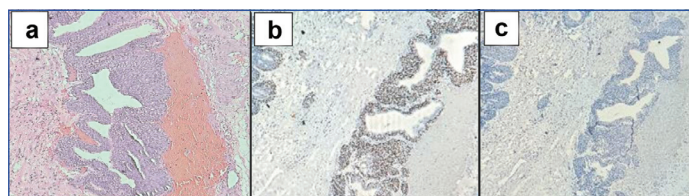
Results of AMACR staining	Mimickers	Well differentiated adenocarcinoma	Total
Positive	02	8	10
Negative	60	0	60
Total	62	8	70

[Table/Fig-3]: Results of AMACR staining in mimickers and well differentiated adenocarcinoma prostate.

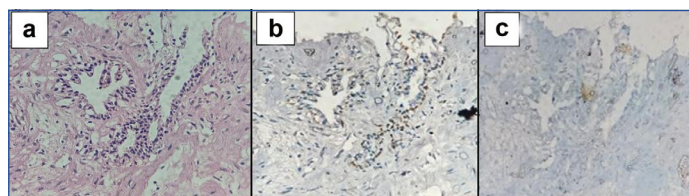
Various H&E staining with immunohistochemistry staining of AMACR and p63 are been depicted in [Table/Fig-4-8] which shows mimickers and prostate adenocarcinoma showing immunolocalisation of both the markers.



[Table/Fig-4]: a) Squamous metaplasia (H&E stain, 40X), b) Squamous metaplasia nuclear staining with p63 (IHC stain 40X), c) squamous metaplasia negative staining with AMACR (IHC stain 40X).

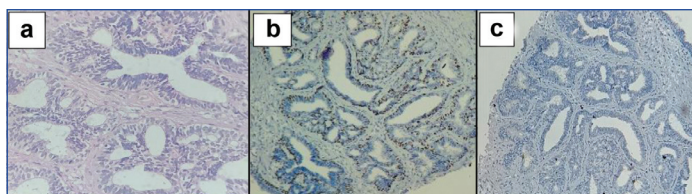


[Table/Fig-5]: a) Basal cell hyperplasia (H&E stain, 40X), b) Basal cell hyperplasia nuclear staining with p63 (IHC stain 40X), c) Basal cell hyperplasia negative staining with AMACR (IHC stain 40X).

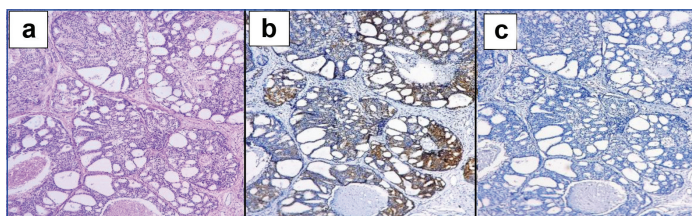


[Table/Fig-6]: a) Low grade PIN (H&E stain, 40X), b) Low grade PIN nuclear staining with p63 (IHC stain 40X), c) Low grade PIN negative staining with AMACR (IHC stain 40X).

Out of 70 cases, 04 cases (04/70) in which both p63 and AMACR were negative. One case was in the category of suspicious for



[Table/Fig-7]: a) High grade PIN (H&E stain, 40X). b) High grade PIN nuclear staining with p63 (IHC stain 40X). c) High grade PIN negative staining with AMACR (IHC stain 40X).



[Table/Fig-8]: a) Prostatic adenocarcinoma (H&E stain, 40X). b) Prostatic adenocarcinoma-diffuse cytoplasmic staining with AMACR (IHC stain 40X). c) Prostatic adenocarcinoma negative staining with p63 (IHC stain 40X).

malignancy and 03 cases were in mimickers of prostatic lesions. These slides were reviewed with different pathologist again for histomorphology features. The histopathologic diagnosis was given and it remained the [Table/Fig-9].

Case	Histopathology diagnosis	p63	AMACR
Case 1	BPH with low grade PIN	Negative	Negative
Case 2	BPH with low grade PIN	Negative	Negative
Case 3	BPH with low grade PIN	Negative	Negative
Case 4	Suspicious for malignancy	Negative	Negative

[Table/Fig-9]: Histopathology and IHC results in 04 cases with p63 and AMACR negativity.

DISCUSSION

Prostatic specific antigen is widely used as a cancer serum marker which has led to significant increase in the number of prostatic needle biopsy performed [15]. However, the test has been criticized as it is been seen increased in inflammations and various other lesions of prostate.

The diagnosis of prostate adenocarcinoma in biopsy can be challenging if small foci of atypical glands is seen. It can also be difficult due to various mimickers of prostate lesions like basal cell hyperplasia, squamous metaplasia, low grade and high grade prostatic intraepithelial neoplasia, atrophy and seminal vesicle. Hence, recently, IHC using monoclonal antibodies against basal cell markers like p63 and AMACR for prostatic adenocarcinoma have been used as adjuvant with morphology in diagnosing prostatic mimickers. This utility have increased diagnostic accuracy of prostate adenocarcinoma worldwide for better treatment [16].

Multiple studies and reports have been done worldwide and have stated the utility of AMACR immunostain in the diagnosis of prostatic adenocarcinoma, making AMACR a very useful, important and diagnostic IHC marker for diagnosing prostate adenocarcinoma. A few studies have shown AMACR expression in high grade prostatic intraepithelial neoplasia also. [17] AMACR is found to be more sensitive and specific when used in combination with basal cell markers like p63. In the present study, a benign and a malignant marker i.e. both p63 and AMACR antibodies were used to demonstrate the expression of these markers in differentiating between adenocarcinoma and prostatic mimickers [Table/Fig-10] [7,18-20].

Sadeghifar M et al., [18] studied p63 expression on a large number of cases and showed a strong diffuse positivity of p63 protein expression in basal cells and hyperplastic prostate glands, versus a patchy expression in prostate atrophy and high grade prostate intraepithelial neoplasia. Moreover, the study of Sadeghifar M et al.,

IHC	Present study	Jiang Z et al., 2005 [7]	Sadeghifar M et al., 2021 [18]	Shah RB et al., 2002 [19]	Okonkwo DI et al., 2021 [20]
p63					
Benign/mimickers	56/70	56/138	27/98	78/175	86/199
Malignant	00/70	00/138	01/98	00/175	00/199
AMACR					
Benign/mimickers	00/70	00/138	04/98	00/175	12/199
Malignant	10/70	78/138	66/98	67/175	101/199

[Table/Fig-10]: Comparative table of our study with other authors [7,18-20].

has suggested that benign lesions High Molecular Weight Cytokeratin (HMWCK) and p63 were found positive in all cases of 60 patients while negative in malignant lesions of prostate. Jiang and co-workers [7] used a triple-antibody cocktail of AMACR, HMWCK 34βE12, and p63 to identify prostate carcinomas and showed highly sensitive and specific marker. Hence, it was concluded that AMACR to be used with a basal cell marker in an antibody cocktail for diagnostic assessment in suspicious lesions of prostate tissues. Shah RB et al., [19] conducted a study for comparing specific basal cell biomarkers p63 and 34βE12 to diagnose prostate cancer. They reported that none of the identified prostate cancer specimens (100% specificity) had responded to these biomarkers. They concluded that 34βE12 and p63 are highly specific for the basal cell hyperplasia. According to a study by Okonkwo DI et al., [20] the AMACR had a sensitivity of 90% specificity of 100%. The malignant lesions of prostate were identified in 36 of 40 cases. The study has shown statistically significant difference in benign and malignant prostatic lesions with expression of AMACR showing p-value=0.001.

In the present study, utility of AMACR and p63 monoclonal antibodies were found AMACR with a sensitivity and specificity of 100% and p63 with a sensitivity of 93.3% and specificity of 100%. There was a statistically significant relationship between p63 and AMACR IHC staining in differentiation mimickers from adenocarcinoma with p-value=<0.001. 04 cases (04/70) in which both p63 and AMACR were negative. Out of 04 cases one case was suspicious for malignancy and 03 cases were mimickers of prostatic lesions. These cases in which we can have negative results for both p63 and AMACR, additional IHC markers can be studied like nkx3.1 [21, 22].

Limitation(s)

Due to study limitation to two immunohistochemistry markers additional markers could not be studied which was seen in 4 cases were both p63 and AMACR were negative.

CONCLUSION(S)

Immunohistochemistry using p63 and AMACR is of great additional value in differentiating prostatic mimickers from well differentiated adenocarcinoma in morphologic challenging cases. Thus, their use to ascertain the exact nature of pathology on difficult small prostate samples obtained by core-needle biopsy to minimize the impacts of under and overtreatment of patients.

REFERENCES

- [1] Rawla P. Epidemiology of prostate cancer. World Journal of Oncology. 2019;10(2):63. Doi: 10.14740/wjon1191.
- [2] Taitt HE. Global trends and prostate cancer: A review of incidence, detection, and mortality as influenced by race, ethnicity, and geographic location. American Journal of Men's Health. 2018;12(6):1807-23. Doi: 10.1177/1557988318798279.
- [3] Zhang K, Bangma CH, Roobol MJ. Prostate cancer screening in Europe and Asia. Asian Journal of Urology. 2017;4:86-95. Doi: 10.1016/j.ajur.2016.08.010.
- [4] Cho JM, Lee SW, Kang JY, Yoo TK. Safety and efficacy of combined transrectal ultrasound-guided prostate needle biopsy and transurethral resection of the prostate. Korean Journal of Urology. 2010;51(2):101-05. Doi: 10.4111/kju.2010.51.2.101.
- [5] Hasan IA, Gaidan HA, Al-Kaabi MM. Diagnostic value of cytokeratin 34 beta e12 (Ck34βe12) and α-methylacyl-coa racemase (amacr) immunohistochemical expression in prostatic lesions. Iranian Journal of Pathology. 2020;15(3):232.

- [6] Tan SH, Young D, Chen Y, Kuo HC, Srinivasan A, Dobi A, et al. Prognostic features of Annexin A2 expression in prostate cancer. *Pathology*. 2021;53(2):205-13. Doi: 10.1016/j.pathol.2020.07.006.
- [7] Jiang Z, Li C, Fischer A, Dresser K, Woda BA. Using an AMACR (P504S)/34betaE12/p63 cocktail for the detection of small focal prostate carcinoma in needle biopsy specimens. *Am J Clin Pathol*. 2005;123:231-36. Doi: 10.1309/1g1nk9dbgnb792l.
- [8] Varma M, Jasani B. Diagnostic utility of immunohistochemistry in morphologically difficult prostate cancer: Review of current literature. *Histopathology*. 2005;47(1):01-06. Doi: 10.1111/j.1365-2559.2005.02188.x.
- [9] Strigley JR. Benign mimickers of prostatic adenocarcinoma. *Modern Pathology*. 2004;17(3):328-48. Doi: 10.1038/modpathol.3800055.
- [10] Mahapatra QS, Mohanty P, Nanda A, Mohanty L. Histomorphological study of prostatic adenocarcinoma and its mimics. *Indian Journal of Pathology and Microbiology*. 2019;62(2):251. Doi: 10.4103/IJPM.IJPM_322_18.
- [11] Rathod SG, Jaiswal DG, Bindu RS. Diagnostic utility of triple antibody (AMACR, HMWCK and P63) stain in prostate neoplasm. *Journal of Family Medicine and Primary Care*. 2019;8(8):2651. Doi: 10.4103/jfmpc.jfmpc_432_19.
- [12] Kalantari MR, Anvari K, Jabbari H, Tabrizi FV. p63 is more sensitive and specific than 34βE12 to differentiate adenocarcinoma of prostate from cancer mimickers. *Iranian Journal of Basic Medical Sciences*. 2014;17(7):497. Doi: 10.1309/JCFW75KGFWQUHVQD.
- [13] Browne TJ, Hirsch MS, Brodsky G, Welch WR, Loda MF, Rubin MA, et al. Prospective evaluation of AMACR (P504S) and basal cell markers in the assessment of routine prostate needle biopsy specimens. *Human Pathology*. 2004;35(12):1462-68. Doi: 10.1016/j.humpath.2004.09.009.
- [14] Humphrey PA. Diagnosis of adenocarcinoma in prostate needle biopsy tissue. *Journal of Clinical Pathology*. 2007;60(1):35-42. Doi: 10.1136/jcp.2005.036442.
- [15] Malik N, Maheshwari V, Aijaz M, Afroz N. Diagnostic significance of combined immunohistochemical panel of p63, High Molecular Weight Cytokeratin (34betaE12) and α-Methyl Acyl Co A Racemase (AMACR) in resolving suspicious foci in prostatic lesions. *Annals of Cytology and Pathology*. 2022;7(1):029-34. <https://doi.org/10.17352/acp.000026>.
- [16] Luo J, Zha S, Gage WR, Dunn TA, Hicks JL, Bennett CJ, et al. α-Methylacyl-CoA racemase: A new molecular marker for prostate cancer. *Cancer Research*. 2002;62(8):2220-06.
- [17] Ng WW, Koh M, Tan SY, Tan PH. Is triple immunostaining with 34βE12, p63, and racemase in prostate cancer advantageous? A tissue microarray study. *American Journal of Clinical Pathology*. 2007;127(2):248-53. PMID: 25429340.
- [18] Sadeghifar M, Madani S, Khazaei S, Izadi B, Kanani M, Roozbahani N, et al. Evaluation of the diagnostic value of immunohistochemistry staining for P63, Alpha-methyl Acyl-CoA Racemase, CK5/6, and 34 [beta] E12 in prostate carcinoma. *Clinical Cancer Investigation Journal*. 2021;10(4):214. Doi:10.4103/ccij.ccij_68_20.
- [19] Shah RB, Zhou M, LeBlanc M, Snyder M, Rubin MA. Comparison of the basal cell-specific markers, 34betaE12 and p63, in the diagnosis of prostate cancer. *Am J Surg Pathol*. 2002;26:1161-68. Doi: 10.1097/00000478-200209000-00006.
- [20] Okonkwo DI, Raphael S, Anunobi CC, Jibrin PG. Diagnostic utility of immunochemical technique using p63 and Alpha Methylacyl Coenzyme A Racemase (AMACR) in the diagnosis of core-needle biopsy of the prostate: Experience in a tertiary academic institution in Nigeria. *Annals of Tropical Pathology*. 2021;12(1):19. Doi: 10.4103/atp.atp_44_20. DOI: 10.4103/atp.atp_44_20.
- [21] Singh V, Manu V, Malik A, Dutta V, Mani NS, Patrikar S, et al. Diagnostic utility of p63 and α-methyl acyl Co A racemase in resolving suspicious foci in prostatic needle biopsy and transurethral resection of prostate specimens. *Journal of Cancer Research and Therapeutics*. 2014;10(3):686.
- [22] Gurel B, Ali TZ, Montgomery EA, Begum S, Hicks J, Goggins M, et al. NKX3. 1 as a marker of prostatic origin in metastatic tumors. *The American Journal of Surgical Pathology*. 2010;34(8):1097.

PARTICULARS OF CONTRIBUTORS:

1. Postgraduate Student, Department of Pathology, Bharati Vidyapeeth (DTU) Medical College, Pune, Maharashtra, India.
2. Professor, Department of Pathology, Bharati Vidyapeeth (DTU) Medical College, Pune, Maharashtra, India.
3. Associate Professor, Department of Pathology, Bharati Vidyapeeth (DTU) Medical College, Pune, Maharashtra, India.
4. Assistant Professor, Department of Pathology, Bharati Vidyapeeth (DTU) Medical College, Pune, Maharashtra, India.

NAME, ADDRESS, E-MAIL ID OF THE CORRESPONDING AUTHOR:

Parineeta Shelke,
Assistant Professor, Department of Pathology, Bharati Vidyapeeth (Deemed to be University) Medical College, Pune, Maharashtra, India.
E-mail: parineta.shelke@bharativedyapeeth.edu

PLAGIARISM CHECKING METHODS: [\[Jain H et al.\]](#)

- Plagiarism X-checker: Sep 14, 2022
- Manual Googling: Nov 15, 2022
- iThenticate Software: Nov 19, 2022 (20%)

ETYMOLOGY: Author Origin**AUTHOR DECLARATION:**

- Financial or Other Competing Interests: None
- Was Ethics Committee Approval obtained for this study? Yes
- Was informed consent obtained from the subjects involved in the study? Yes
- For any images presented appropriate consent has been obtained from the subjects. No

Date of Submission: **Sep 01, 2022**
Date of Peer Review: **Oct 05, 2022**
Date of Acceptance: **Nov 26, 2022**
Date of Publishing: **Feb 01, 2023**