

Physical Rehabilitation of Patient with Infrarenal Abdominal Aortic Aneurysm Presenting with Hydrocele and Inguinal Hernia: A Case Report

DHANUSH KOTIAN¹, ABEESHNA ASHOK²

ABSTRACT

Infrarenal Abdominal Aortic Aneurysm (AAA) is an abnormal dilation of distal abdominal aorta. The risk factors are age older than 60 years, smoking, hypertension and caucasian ethnicity. Testicular pain is an uncommon clinical presentation. There is a high prevalence of inguinal hernia in patients with infrarenal AAA. The purpose of the present case report is to describe the functional activity limitation in a patient affected by an infrarenal AAA presenting as a symptom of inguinal hernia and groin pain despite successful infrarenal AAA repair with aortofemoral bypass surgery and bilateral inguinal hernia repair. A 62-year-old male patient, presented with pain in the groin region and mild swelling over the scrotal region, which was severely limiting his activities of daily living. A Computerised Tomography (CT) angio abdomen revealed a fusiform aneurysm on the distal abdominal aorta and a saccular aneurysm of bilateral common iliac arteries. Given the minimum of four days of referral waiting time to receive treatment for infrarenal AAA, the patient underwent surgery and was followed by the postoperative physiotherapy intervention. The rehabilitation programme started five days postsurgery. The treatment goals directed mainly decreasing postoperative pulmonary complications and improving functional mobility. The present case report contributes new light on the possible pathogenesis and timely management. It reports the unexpected and unusual presentation of the disease and unveiling the link between the presentation of infrarenal AAA and inguinal hernia and hydrocele.

Keywords: Aortogram, Aneurysm, Physical therapy

CASE REPORT

A 62-year-old male patient was referred to the Department of Physiotherapy by cardiothoracic and vascular surgery unit on Postoperative Day (POD) 5. The chief complaint was pain, over the abdominal surgical incision site along with the movement restriction in the lower limb. The pain was sudden in onset, gradually progressive, dull aching type. The pain was aggravating during activity and patient also reported pain intensity score of seven on Numerical Pain Rating Scale (NPRS). The patient also presented with swelling in the lower limb and scrotum as well. He was overweight, with a Body Mass Index (BMI) of 28.6 kg/m². The history revealed that, the patient was in his usual state of health five months ago, when he had pain in his groin region and also noticed mild swelling over the scrotal area. The pain was sudden in onset and gradually progressive, limiting his activities of daily living. The patient was stable and refused to consult the physician. An increase in pain severely affected the patient's functional mobility. Then the patient consulted a nearby local hospital, where the physician advised him for a CT scan. The result demonstrated an infrarenal AAA along with the bilateral inguinal hernia and right-sided hydrocele. The physician recommended better care for the patient, and was referred to a multispecialty hospital for further management. As per the suggestion, the patient visited the hospital, where transthoracic echocardiography was done before the surgery, which demonstrated mild left ventricular dysfunction with an Left Ventricular Ejection Fraction (LVEF) of 45%. The aneurysm repair was delayed for three days after the admission to the hospital due to fluctuations in blood pressure. After the vitals were normalised, the surgeons opted for infrarenal AAA repair with aortobifemoral bypass surgery and bilateral inguinal hernia repair.

The surgeons could not perform a hydrocelectomy since, the vitals were unstable. The surgery was performed on the 4th day of hospital admission. Postoperatively the patient got shifted to the postoperative care unit, with an unstable blood saturation level of 80%. The patient was on 6 L of supplemental oxygen and weaned

off from the nasal cannula on POD 5 since, the patient maintained an oxygen saturation level of 97%. As the condition was resolving and the patient was symptomatically improving and got shifted to the ward. As per the surgeon's order, the physiotherapy assessment and management were started on the same day in the ward.

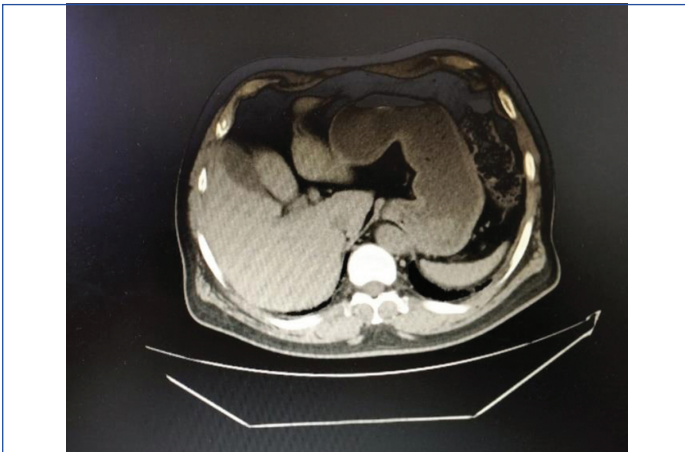
The surgical history revealed that, the patient underwent Percutaneous Transluminal Coronary Angioplasty (PTCA) to Left Anterior Descending artery (LAD) 20 years ago. Then, the patient continued anticoagulants only for four years and stopped the medication afterward without any medical advice. And again, he underwent Coronary Artery Bypass Grafting (CABG) surgery with three grafts a year ago. Patient is currently under statins and antacids and had had stopped smoking and alcohol consumption 20-year-ago after the PTCA surgery.

Clinical Findings

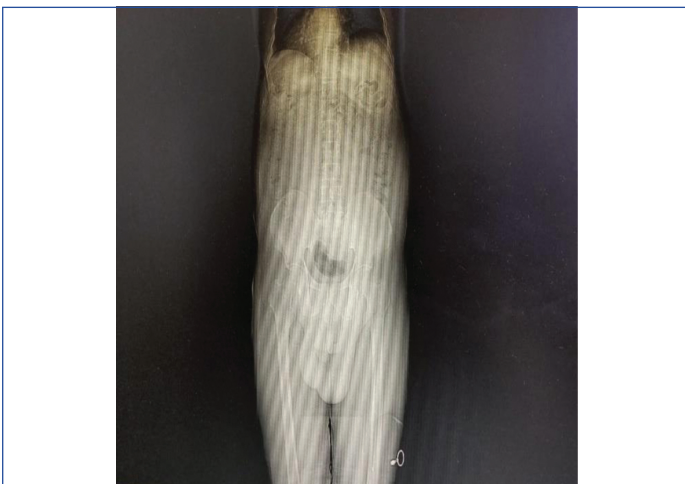On observation, the chest findings revealed that, the patient had thoracoabdominal breathing pattern and there was a healed sternotomy surgical scar present. The abdominal findings are midline abdominal incision, incision over the paraumbilical region and swelling of the scrotum. There was a surgical incision present over the left groin region, healed surgical incision scar and oedema present over the left lower limb. On examination, the chest findings showed normal chest symmetry and the length of the sternotomy incision is 32 cm measured using an inch of tape. The length of the surgical incision scar on the left leg measures about 33 cm, non pitting oedema over the left lower limb. Normal breath sounds heard on pulmonary auscultation. S1 and S2 were present on cardiac auscultation. The girth measurements are given in [Table/Fig-1]. To get a clearer picture of the lesion, the patient underwent a CT angio abdomen before surgery, which demonstrated a fusiform aneurysm of the distal abdominal aorta [Table/Fig-2] and X-ray demonstrating left-sided hydrocele with the marked swelling [Table/Fig-3]. CT aortogram showing saccular aneurysm of bilateral common iliac

Location	Right lower limb	Left lower limb
Upper thigh	Couldn't assess because of the incision pain	Couldn't assess because of the incision pain.
Middle thigh	46 cm	61 cm
Lower thigh	39 cm	50 cm
Upper leg	34.5 cm	40 cm
Mid leg	32.5 cm	40 cm
Ankle	35 cm	24 cm
Foot	56.3 cm	66.5 cm

[Table/Fig-1]: Girth measurement.

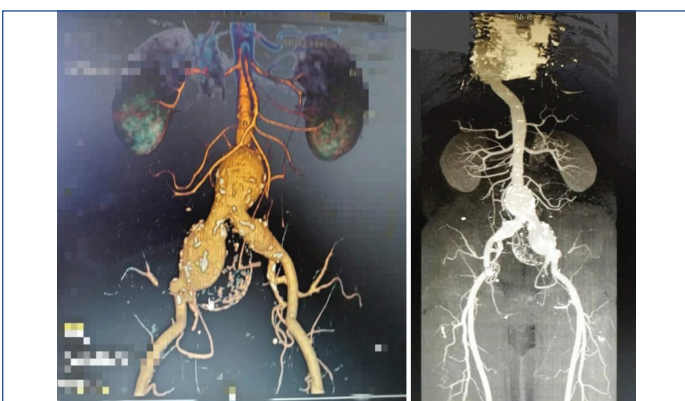

[Table/Fig-2]: Transverse view of CT angio showing fusiform aneurysm of distal abdominal aorta.



[Table/Fig-3]: X-ray showing left-sided hydrocele with the marked swelling.

arteries and infrarenal abdominal aortic artery aneurysm [Table/Fig-4]. CT angiogram showing fusiform aneurysm of the distal abdominal aorta [Table/Fig-5].



[Table/Fig-4]: CT aortogram showing saccular aneurysm of bilateral common iliac arteries and infrarenal abdominal aortic artery aneurysm.

[Table/Fig-5]: CT angiogram showing fusiform aneurysm of the distal abdominal aorta. (Images from left to right).

Physiotherapy Intervention

The acute rehabilitation comprised of the following objectives such as, maintenance of the range of motion and strength of the affected limb, preventing postoperative pulmonary complications, and recovery of standing position and walker training with walker support. The patient received physical therapy rehabilitation from POD 5 till discharge (for seven days). The treatment programme consisted 30 minute sessions, each consisting of 15 minutes of exercise in bed (1st session) and 15 minutes of gait training with assistance until discharge from the hospital (2nd session) [1]. On the 5th day, static breathing exercises, incentive spirometry exercises, general relaxation exercises, and general light small muscle training exercises were given, and later, dynamic breathing exercises, physical exercises for medium size and large muscle, and walking with assistance was provided.

The programme usually started with cautious active mobilisation of the joints in the limb with the patient lying supine. Once the ankle joint had been mobilised, the knee and hip were often kept in flexed attitude because of the pain. Then, assisted active flexion and extension of the limb and stretched the hamstrings to gain complete knee extension. From the supine position, the patient was brought into lateral decubitus and then into a sitting place. From the 2nd session after 15 minutes of exercise in bed, the programme focused on the recovery of the upright position and gait. An upright position and gait training were usually aided with walker support. In the beginning, the patient was asked to walk for a 10 metre distance [Table/Fig-6]. The patient performed longer distances progressively. [Table/Fig-7] shows the outcome measures taken pre and post physiotherapy management [2-5]. Barthel index showed 30% increase in the score and there was 30% decrease in both anxiety and depression components of Hospital Anxiety and Depression Scale (HADS). The pain intensity shown reduction of 28.6% and 50% on activity and on rest, respectively. There was 100% decrease in dyspnoea on Borg dyspnoea scale [5].

From the 1 st session of physiotherapy	From the 2 nd session of physiotherapy
<ul style="list-style-type: none"> Active mobilisation of hip, knee, and ankle Diaphragmatic breathing exercises Incentive spirometry and thoracic expansion exercises. Sitting and standing position recovery 	<ul style="list-style-type: none"> Standing position recovery Assisted exercises in an upright position Walking training with walker support

[Table/Fig-6]: Early postoperative rehabilitation programme.

Parameters	Pretreatment	Post-treatment	Decrease (%)	Increase (%)
Barthel index [2]	50/100	65/100		30
HADS [3]	Depression-10	Depression-07	30	
	Anxiety-10	Anxiety-07	30	
NPRS [4]	On rest-04	On rest-02	50	
	On activity-07	On activity-05	28.6	
Borg dyspnoea scale [5]	2	0	100	

[Table/Fig-7]: Outcome measures [2-5].

The patient got discharged two week after the surgery. The patient was symptomatically better at the time of discharge and patient was asked to come for the review after three months for the fitness evaluation for hydrocelectomy. Home advices such as deep breathing exercises, posture correction exercises, ambulation training, upper limb and lower limb strengthening exercises with available weights and general awareness on physical activity were given.

DISCUSSION

An aneurysm is an abnormal dilation and weakening of an area of the arterial vessel this leads to tearing and haemorrhage into the wall (i.e., dissection) or surrounding tissue (i.e., rupture). An aortic aneurysm often presents as an acute dissection or rupture without

any prior symptoms [1]. Studies utilising the help of ultrasound screening revealed that, 4%-8% of the male geriatric population have an occult AAA. Ruptured aneurysms have a fatality rate of 50% to 95%, accounting for the 10th leading cause of death in men older than 55 years [6]. They are usually present with the AAA the infrarenal portion of the abdominal aorta and just proximal to the distal portion of the iliac arteries. Inguinal hernia is a common clinical entity that presents along with the AAA. Elastin and collagen fiber abnormalities and disorders play a major role in this. Variations in the levels of collagenase, elastase, and antiproteases are important mechanisms in the pathophysiology of both diseases [7]. Hydrocele is defined as, an abnormal collection of serous fluid in the space between the parietal and visceral layers of the tunica vaginalis, termed the cavum peritoneum scroti. Hydrocele is the most common cause of painless nonacute scrotal swelling in men and the normal scrotum contains about 2-3 mL of fluid between the tunics layers [8].

The described mortality rate of patients with a ruptured AAA is, as high as, 90%. In contrast, mortality rates for patients undergoing elective AAA repair are typically less than 10%. Accordingly, it is important to diagnose AAA before rupture [9]. It is estimated that, 4% to 8% of men and 0.5% to 2% of women older than age 60 years have AAA. Larger aneurysms have an associated higher risk of rupture. In addition, larger aneurysms expand at a faster rate than smaller aneurysms. A 5 cm aneurysm has a predictable 20% annual risk of rupture and 6 cm aneurysm has a predictable 40% annual risk of rupture [10]. When symptoms are produced they typically include deep, boring pain in the abdomen, pain, tenderness on palpation, and a prominent pulsating mass in the abdomen [11,12]. The functional abilities of the patient is found to be better with current rehabilitation protocol [13]. Literature suggests that, there are no conservative management available to treat abdominal aortic aneurysm and the role of physical therapy mainly comes in the education of risk factor prevention, cessation of smoking, signs and symptoms and public education. Preoperative physical therapy management has shown improvement in postoperative outcome. Postoperative management should focus on the prevention of postoperative complications and early mobilisation [14,15].

The present case report suggests that, an abdominal aneurysm can have many other presentations because of the compression on the surrounding structures such as bilateral groin pain, as well as, testicular pain and also, the report gives the new insight into the barriers in the management.

CONCLUSION(S)

The authors would like to conclude by saying that, an infrarenal AAA can be presented as an inguinal hernia and hydrocele. Inguinal hernia and hydroceles are both characterised by swelling of the groin and scrotum. Hence, early physiotherapy intervention such as pulmonary rehabilitation and mobilisation helps in faster recovery of the patient undergoing AAA repair and bilateral inguinal hernia repair.

REFERENCES

- [1] Ehrman JK, Fernandez AB, Myers J, Oh P, Thompson PD, Keteyian SJ. Aortic aneurysm: Diagnosis, management, exercise testing, and training. *Journal of Cardiopulmonary Rehabilitation and Prevention*. 2020;40(4):215-23.
- [2] Uchinaka EI, Hanaki T, Morimoto M, Murakami Y, Tomoyuki M, Yamamoto M, et al. The Barthel Index for predicting postoperative complications in elderly patients undergoing abdominal surgery: a prospective single-center study. *In vivo*. 2022;36(6):2973-80.
- [3] Tomee SM, Gebhardt WA, De Vries JP, Hamelinck VC, Hamming JF, Lindeman JH. Patients' perceptions of conservative treatment for a small abdominal aortic aneurysm. *Patient Prefer Adherence*. 2018;15(12):119-128.
- [4] Tanaka A, Al-Rstum Z, Leonard SD, Bri'Ana DG, Yazij I, Sandhu HK, et al. Intraoperative intercostal nerve cryoanalgesia improves pain control after descending and thoracoabdominal aortic aneurysm repairs. *The Annals of Thoracic Surgery*. 2020;109(1):249-54.
- [5] Nolan CM, Kaliaraju D, Jones SE, Patel S, Barker R, Walsh JA, et al. Home versus outpatient pulmonary rehabilitation in COPD: a propensity-matched cohort study. *Thorax*. 2019;74(10):996-98.
- [6] Chu EC. Large abdominal aortic aneurysm presented with concomitant acute lumbar disc herniation-a case report. *Journal of Medicine and Life*. 2022;15(6):871.
- [7] Megalopoulos A, Ioannidis O, Varnalidis I, Ntoupoura M, Tsigriki L, Alexandris K, et al. High prevalence of abdominal aortic aneurysm in patients with inguinal hernia. *Biomed Pap Med Fac Univ Palacky Olomouc Czech Repub*. 2019;163(3):247-52.
- [8] Carlisi E, Caspani P, Morlino P, Bardoni MT, Lisi C, Bejor M, et al. Early rehabilitative treatment after infrainguinal lower limb bypass surgery. *Acta Bio Medica: Atenei Parmensis*. 2017;88(2):167.
- [9] Clancy K, Wong J, Spicher A. Abdominal aortic aneurysm: a case report and literature review. *The Permanente Journal*. 2019;23:18.218.
- [10] Keisler B, Carter C. Abdominal aortic aneurysm. *Am Fam Physician*. 2015;91(8):538-43.
- [11] Fink HA, Lederle FA, Roth CS, Bowles CA, Nelson DB, Haas MA. The accuracy of the physical examination to detect abdominal aortic aneurysm. *Arch Intern Med*. 2000;160(6):833-36. Doi: <https://doi.org/10.1001/archinte.160.6.833>.
- [12] Chukwubuike KE. Complicated inguinal hernia in children: an experience in a developing country. *J Med Sci*. 2020;6(1):01-03.
- [13] Rapsang AG, Shyam DC. Scoring systems in the intensive care unit: a compendium. *Indian journal of critical care medicine: peer-reviewed, official publication of Indian Society of Critical Care Medicine*. 2014;18(4):220.
- [14] Myers J, Mcelrath M, Jaffe A, Smith K, Fonda H, Vu A, et al. A randomized trial of exercise training in abdominal aortic aneurysm disease. *Medicine and Science in Sports and Exercise*. 2014;46(1):02-09.
- [15] Pouwels S, Willigendael EM, Van Sambeek MR, Nienhuijs SW, Cuyper PW, Teijink JA. Beneficial effects of pre-operative exercise therapy in patients with an abdominal aortic aneurysm: a systematic review. *European Journal of Vascular and Endovascular Surgery*. 2015;49(1):66-76.

PARTICULARS OF CONTRIBUTORS:

1. Postgraduate Student, Nitte Institute of Physiotherapy, NITTE (Deemed to be University), Deralakatte Mangalore, Karnataka, India.
2. Assistant Professor, Nitte Institute of Physiotherapy, NITTE (Deemed to be University), Deralakatte Mangalore, Karnataka, India.

NAME, ADDRESS, E-MAIL ID OF THE CORRESPONDING AUTHOR:

Dr. Abeeshna Ashok,
Assistant Professor, Nitte Institute of Physiotherapy, NITTE (Deemed to be University), Deralakatte Mangalore-575018, Karnataka, India.
E-mail: abeeshnaashok@gmail.com

AUTHOR DECLARATION:

- Financial or Other Competing Interests: None
- Was informed consent obtained from the subjects involved in the study? Yes
- For any images presented appropriate consent has been obtained from the subjects. Yes

PLAGIARISM CHECKING METHODS: [Jan H et al.]

- Plagiarism X-checker: Jan 19, 2023
- Manual Googling: Feb 14, 2023
- iThenticate Software: Mar 03, 2023 (18%)

ETYMOLOGY: Author Origin

EMENDATIONS: 8

Date of Submission: **Jan 18, 2023**
Date of Peer Review: **Feb 07, 2023**
Date of Acceptance: **Apr 19, 2023**
Date of Publishing: **Jun 01, 2023**