

# **An Asymptomatic Tropical Infection in a Pregnancy Complicated by a Hematological Neoplasm-accidental Passenger or Effect of Immunosuppression?**

**Sammya Bhowmick<sup>1</sup>, Chandan Mishra<sup>1</sup>, S. Arulsevi<sup>1</sup> and Tushar Sehgal<sup>1\*</sup>**

<sup>1</sup>Department of Laboratory Medicine, All India Institute of Medical Sciences, New Delhi, India.

## **Authors' contributions**

*This work was carried out in collaboration among all authors. Author Tushar Sehgal designed the study and performed the analysis. Author Sammya Bhowmick wrote the first draft of the manuscript. Author S.Arulsevi managed the analyses of the study. Authors Sammya Bhowmick and Chandan Mishra managed the literature searches. All authors read and approved the final manuscript.*

## **Article Information**

DOI: 10.9734/IBRR/2020/v11i430138

### Editor(s):

(1) Dr. Dharmesh Chandra Sharma, J. A. Groups of Hospital and G. R. Medical College, India.

### Reviewers:

(1) Kueviakoe M. D. Irene, University of Lomé, Togo.

(2) Dr. Najeba Farhad Salih, Koya University, Iraq.

Complete Peer review History: <http://www.sdiarticle4.com/review-history/63268>

**Case Report**

**Received 28 September 2020**

**Accepted 01 December 2020**

**Published 13 January 2021**

## **ABSTRACT**

*Lymphatic filariasis* is a vector borne infection classified under the WHO category of Neglected Tropical Disease (NTD). It is a major public health concern globally. This study describes this vector-borne infection in a young pregnant lady, a known case of chronic myeloid leukemia (CML) on chemotherapy. Such an association is hitherto unreported.

**Keywords:** *Chronic myeloid leukemia; Lymphatic filariasis; neglected tropical disease; pregnancy.*

## **1. INTRODUCTION**

*Lymphatic filariasis* (LF) is a familiar vector-borne disease in various tropical and subtropical

countries. It affects 120 million people worldwide [1]. World Health Organization (WHO) categorizes this communicable disease under the category of NTD [2]. The causative agents

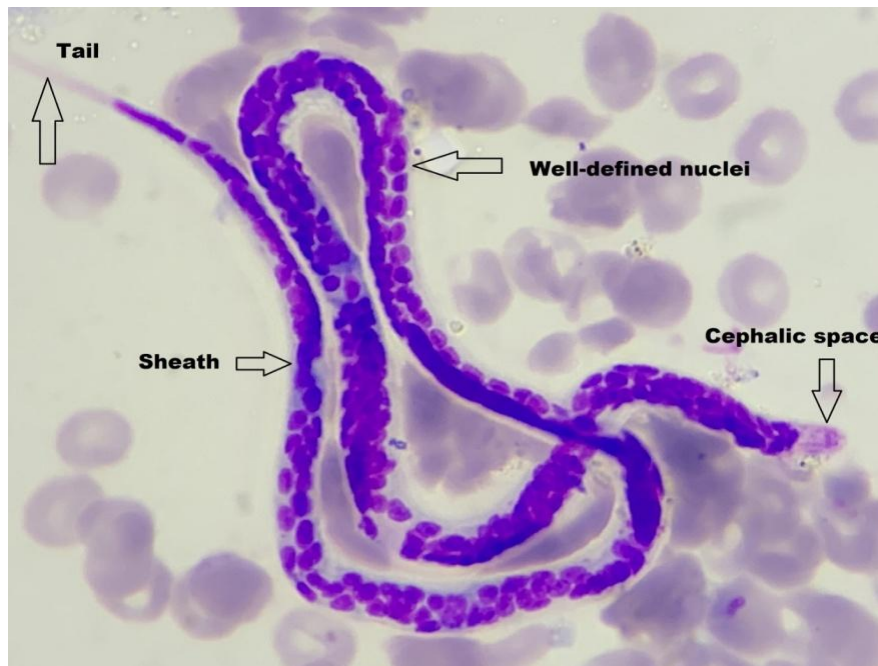
\*Corresponding author: E-mail: Doctusharsehgal@yahoo.co.in;

are filarial nematodes *Wuchereria bancrofti* (WB), *Brugia malayi* (BM) and *Brugia timori* (BT). The vector transmitting the parasite depends on the geographic area and includes species of *Anopheles*, *Culex*, *Aedes* and *Mansonia* mosquitoes [1].

LF may present as asymptomatic, acute, or chronic infections. Majority of affected person shows clinically asymptomatic infection and harbor microfilariae (MF) in their peripheral blood (PB). Acute infection includes fever, epididymo-orchitis, lymphangitis and adenolymphangitis. Chronic disease includes hydrocele, lymphedema and “elephantiasis” (which is irreversible edema of the limb with skin thickening, papillary and nodular growth) [3]. Microscopy is the mainstay for diagnosis of LF. It can be performed on thick and thin blood smears or buffy coat films [1]. However, the sensitivity of MF detection depends on the volume of blood sampled, the time of blood collection and the skill of laboratory physician [3]. There are a few reports of the co-existence of MF in the cancers. This study describes an interesting case of LF in a pregnant lady who was under chemotherapy for CML. Such an association is hitherto unreported. Moreover, the treatment of LF becomes more challenging in pregnancy complicated by CML.

## 2. CASE HISTORY

25-year-old pregnant lady was admitted at 35 weeks of gestation in view of high risk pregnancy. Formerly, in 2014 she was diagnosed with CML and was started on imatinib, a first-generation BCR-ABL tyrosine-kinase inhibitor. In 2016 she conceived while on imatinib, but mindful of the risk of teratogenicity with imatinib she underwent medical termination of pregnancy after one month of conception. Nonetheless, the current pregnancy was a planned one and she was switched to Interferon-alpha (IFN- $\alpha$ ). During this pregnancy a request for complete blood count and blood film were received by laboratory at night. Her haemoglobin was 9.5 gm/dl, with total leucocyte count of  $6.5 \times 10^9/l$ , and platelet count of  $100 \times 10^9/l$ . The absolute eosinophil count was within normal limits. Examination of blood film showed a thread-like, curved and sheathed MF consistent with WB (Fig. 1). This finding was conveyed to the obstetrics team and she was started on oral anti-helminthic medications comprising albendazole and ivermectin. She was not given diethylcarbamazine (DEC) due to its contraindication in pregnancy. She delivered a normal healthy baby and was discharged on DEC. Till last follow up, both mother and child were doing fine.



**Fig. 1.** Photomicrograph shows a thread-like, curved and sheathed microfilaria (*Wuchereria bancrofti*) with tail tip free of nuclei against a background of red blood cells (MGG stain  $\times 1000$ )

### 3. DISCUSSION

LF is an important public health problem in India. It may present as asymptomatic microfilaraemia, lymphatic obstruction or tropical pulmonary eosinophilia [2]. In India, the nematode species that causes LF includes WB mainly and to a lesser extent BM [4]. During a blood meal, an infected mosquito introduces third-stage filarial larvae onto the skin of the human host. They develop in adults that reside in the lymphatics. The early stage of infection is called as the stage of asymptomatic microfilaraemia and is characterized by presence of live adult parasites in the lymphatic system and MF in the blood, without any outward evidence of disease [2]. Once the clinical manifestations develop there is usually absence of microfilaraemia. The laboratory methods that are used for diagnosing active infections with WB are demonstration of MF by microscopy, serology, detection of circulating filarial antigens (CFA) released in the blood by adult worms and detection of filarial DNA by polymerase chain reaction (PCR) [3].

Discernment of MF from PB, bone marrow and other tissues is achieved by screening pathological smears. Microscopy is not sensitive in infections especially those with low density parasitemia and where adult worms are present but no MF [3]. Timing of sample collection is key factor in microscopy as MF of WB and BM display nocturnal periodicity, maximum density is between 10 p.m and 2 a.m in blood [1,5]. LF may be associated with variable PB eosinophilia. Other parasitic conditions with eosinophilia are schistosomiasis, visceral toxocariasis, strongyloidiasis, ancylostomiasis, fascioliasis, trichinellosis, and paragonimiasis [6]. Serology provides an alternative to microscopy. Patients with active filarial infection have elevated levels of antifilarial IgG4 in blood and these can be detected using routine assays [2]. CFA tests are more sensitive than microscopy in detecting MF. Being simple it can be done with finger-prick blood. Moreover, they not dependent upon the presence of MF, therefore, positive even during early stages of disease. Furthermore, they can be done at any time. CFA detection can be performed by immunochromatographic card test or Og4C3 enzyme-linked immunosorbent assay [3]. Real-time and conventional PCR are available for the detection of WB in blood, but are not routinely performed. The best way to prevent LF is to avoid mosquito bites. Annual mass treatment reduces the level of MF in the blood and thus, diminishes transmission of infection.

This is the basis of the global program to eliminate LF [2].

Association of LF with malignancies is described in literature [7]. It raises that the discussion whether they are mere accidentally detected or if these patients are more prone to LF due to their immunocompromised status. Furthermore, as chronic parasitic infections are associated with lower immunosurveillance and chronic antigenic stimulation due to parasites may sustain the proliferation of immunoeffector cells, it appears that MF may have a role in the pathogenesis of neoplasms [7,8]. In this case the patient was a known case of CML. In view of her pregnancy she was switched from Imatinib to IFN- $\alpha$ . After blood smear showed MF she was started on oral anti-helminthic medications. To the best of the knowledge this is the first case of LF in pregnancy complicated by CML. This case also lacked eosinophilia, absence of which may be due to altered immune response secondary to CML or due to oxidative stress accompanying LF.

### 4. CONCLUSION

To conclude, in endemic countries possibility of MF should be kept in mind even in absence of classical clinical presentation or blood eosinophilia and blood smears should be diligently screened by a laboratory physician to ensure that a treatable infection is not missed and appropriate treatment is given in a timely fashion.

### CONSENT

As per international standard or university standard, patients's written consent has been collected and preserved by the authors.

### ETHICAL APPROVAL

It is not applicable.

### COMPETING INTERESTS

Authors have declared that no competing interests exist.

### REFERENCES

1. Shenoy RK. Clinical and pathological aspects of filarial lymphedema and its management. Korean J Parasitol. 2008;46: 119–125.

2. Parasites-*Lymphatic Filariasis*. Available: <https://www.cdc.gov/parasites/lymphaticfilariasis/> Accessed August 2020
3. Musso D. Relevance of the eosinophil blood count in bancroftian filariasis as a screening tool for the treatment. *Pathog Glob Health*. 2013;107:96–102.
4. Sabesan S, P Vanamail P, Raju KHK, Jambulingam P. *Lymphatic filariasis* in India: Epidemiology and control measures. *J Postgrad Med*. 2010;56:232-8.
5. Umashankar T, Yaranal PJ. Microfilaria in bone marrow aspirate: Report of a case. *J Clin Diagn Res*. 2010;6:1294-5.
6. Tefferi A. Blood eosinophilia: A new paradigm in disease classification, diagnosis and treatment. *Mayo Clin Proc*. 2005;80:75-83.
7. Kerketta LS, Ghosh K. Circulating microfilariae in haematological malignancies: Do they have a role in pathogenesis? *J Helminthol*. 2018;92:125-7.
8. Emmanuel B, Kawira E, Ogwang MD, Wabirga H, Magatti J, Nukruma F, et al. African burkitt's lymphoma: Age specific risk and correlation with malaria biomarkers. *Am J Trop Med Hyg*. 2011;84:397–401.

© 2020 Bhowmick et al.; This is an Open Access article distributed under the terms of the Creative Commons Attribution License (<http://creativecommons.org/licenses/by/4.0>), which permits unrestricted use, distribution, and reproduction in any medium, provided the original work is properly cited.

*Peer-review history:*

*The peer review history for this paper can be accessed here:*  
<http://www.sdiarticle4.com/review-history/63268>